

A. De Coninck

Dermatology en Dermatopathology

Zeeland

HUID EN ONCOLOGIE

EEN VERHAAL OVER GOED EN KWAAD

Dr. ARLETTE DE CONINCK UZ Brussel

3 April 2008

BENIGN SKIN TUMOURS

SKIN TAG

GIANT SKIN TAGS

EHLERS-DANLOS SYNDROME

SEBORRHEIC KERATOSIS

SEBORRHEIC KERATOSIS

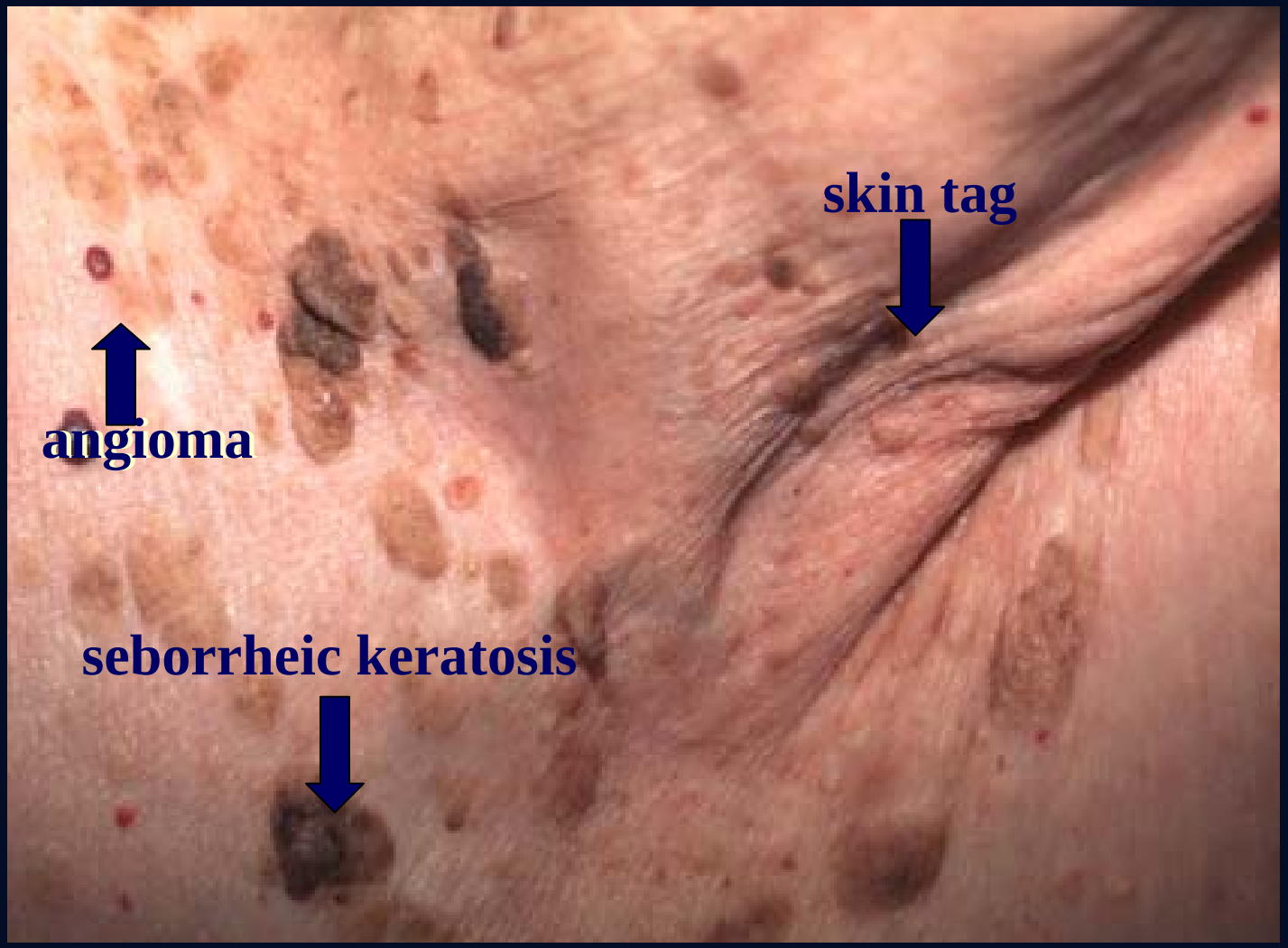
skin tag
angioma
seborrheic keratosis

SEBORRHEIC KERATOSIS

LESER-TRELAT SIGN

EPIDERMAL CYST

DERMOID CYST

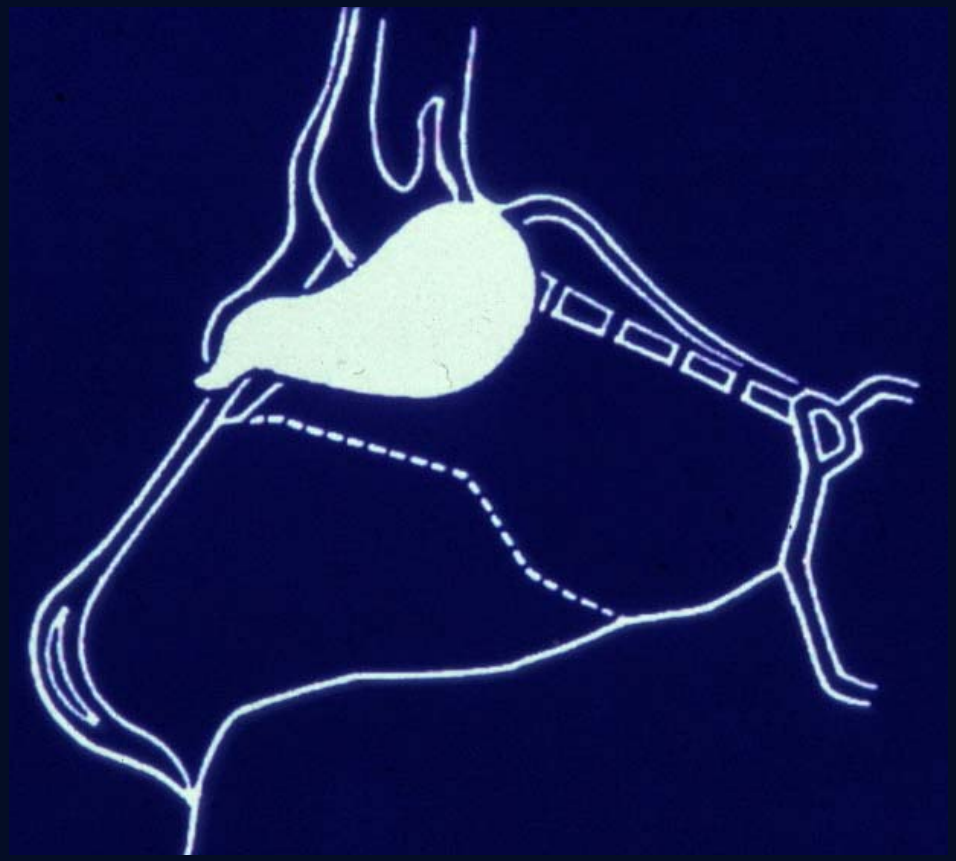

EPIDERMAL CYST

KELOID

EPIDERMAL CYST

META BREASTCARCINOMA

EPIDERMAL CYST?

PILOMATRICOMA

PILOMATRICOMA

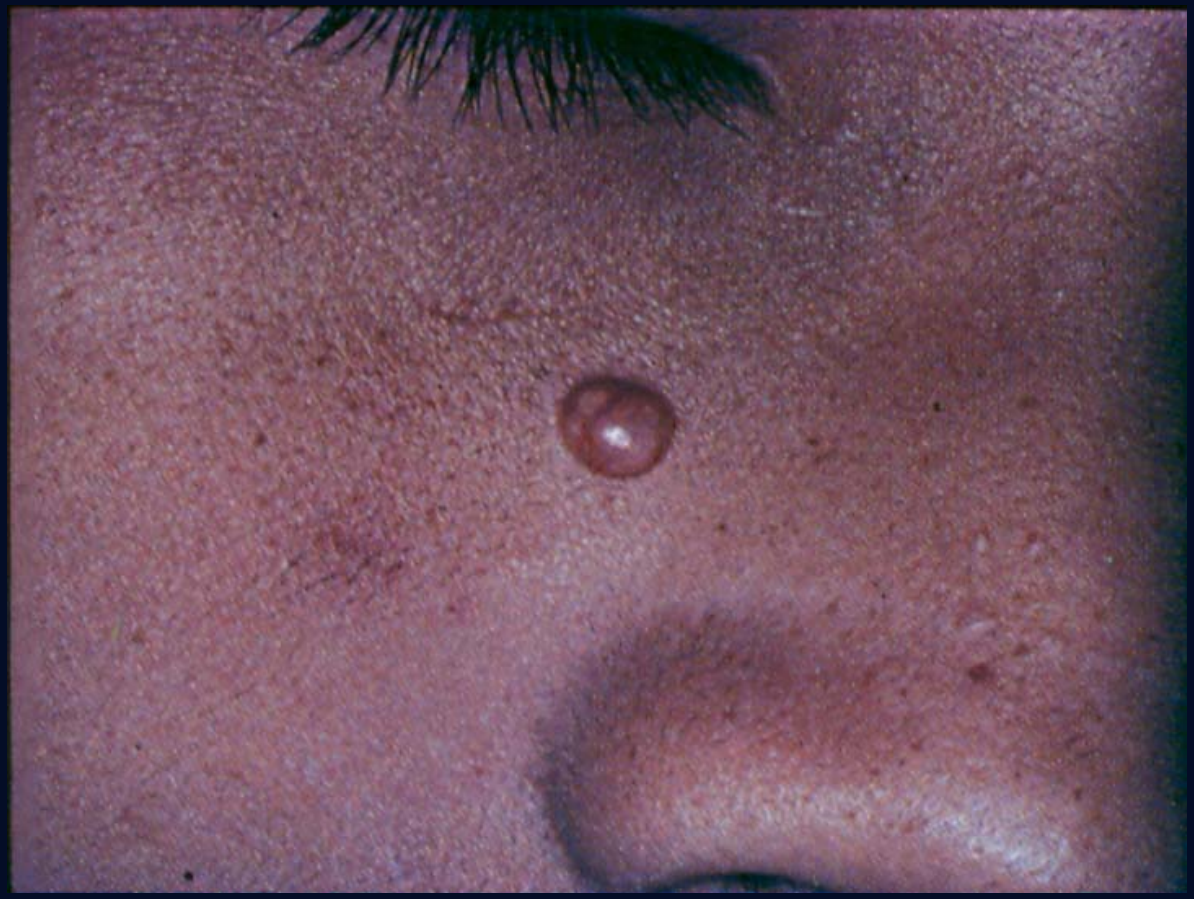

LIPOMA

HERNIA

NAEVUS SEBACEOUS

NAEVUS SEBACEOUS

CAVE: BCC

DERMATOFIBROMA

GRANULOMA PYOGENICUM

HAEMANGIOMA

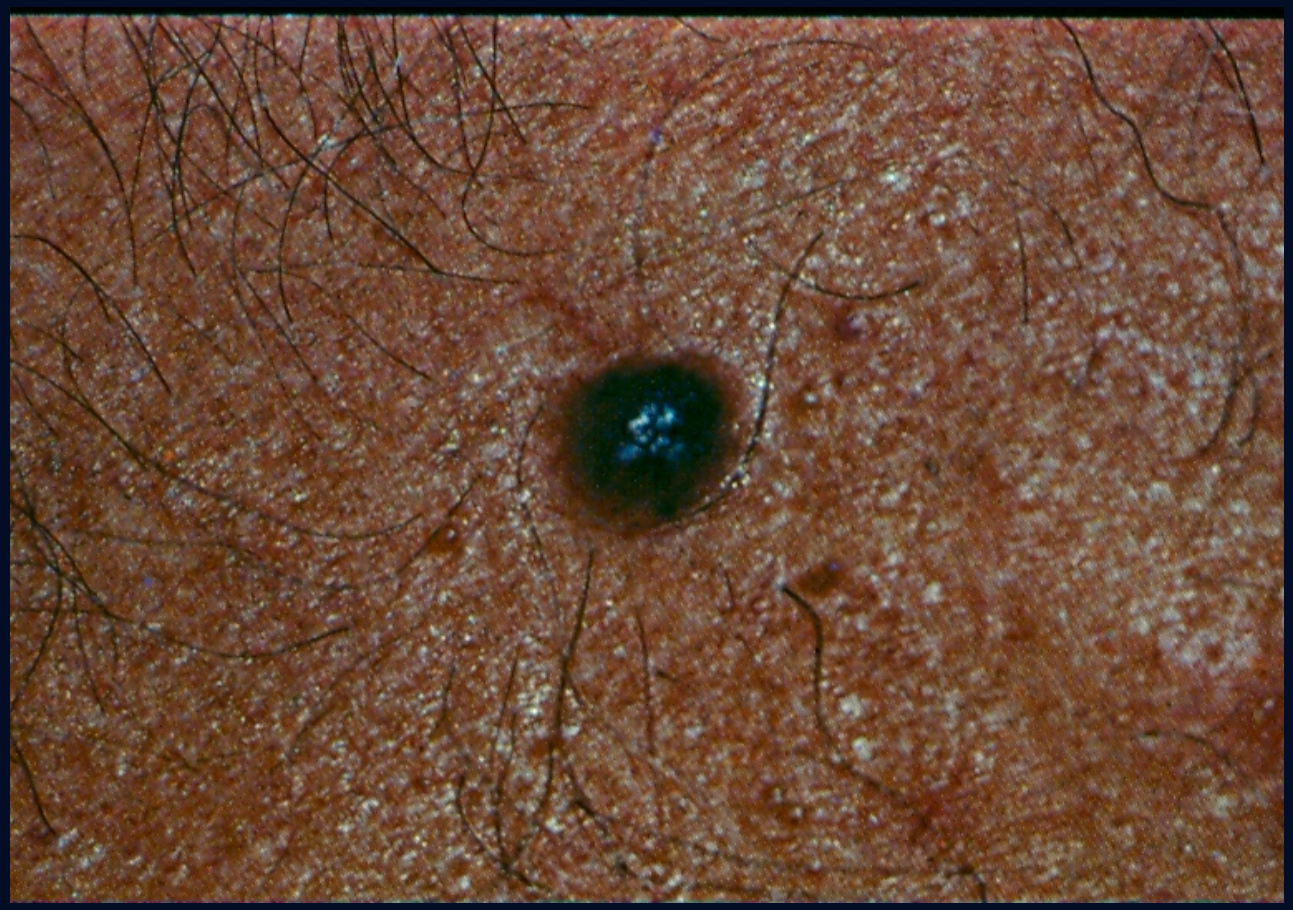

HIDROCYSTOMA

SYRINGOMA

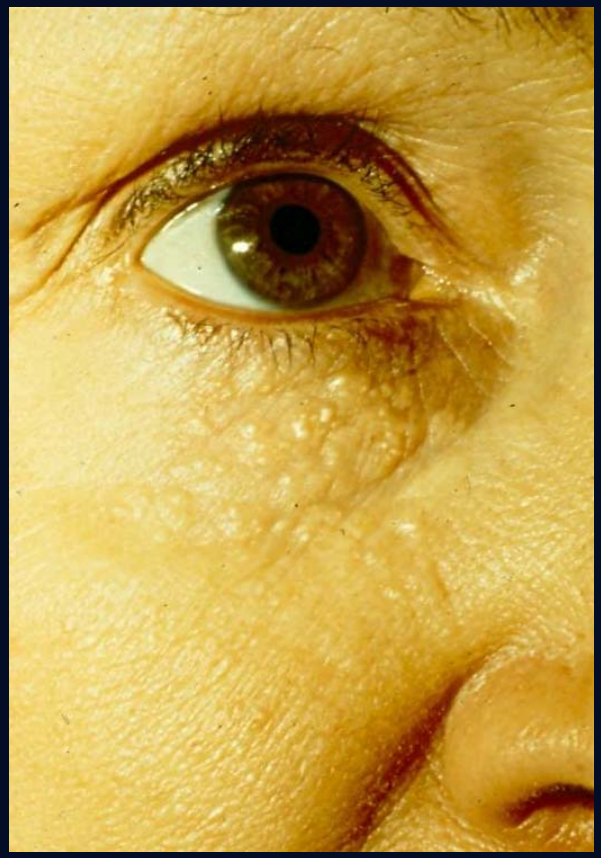

ADENOMA SEBACEUM

TUBEROUS SCLEROSIS

TRICHILEMMONA

MULTIPLE

↓

COWDEN'S SYNDROME

MELANOCYTIC LESIONS

- BECKER'S NAEVUS
- CAFE - AU - LAIT SPOT
- EPHELIDE
- LENTIGO SIMPLEX
- LENTIGO SOLARIS
- MELANOCYTIC NAEVUS

BECKER'S NAEVUS

CAFE-AU-LAIT SPOT

NEUROFIBROMATOSIS

EPHELIDES

LENTIGO SIMPLEX

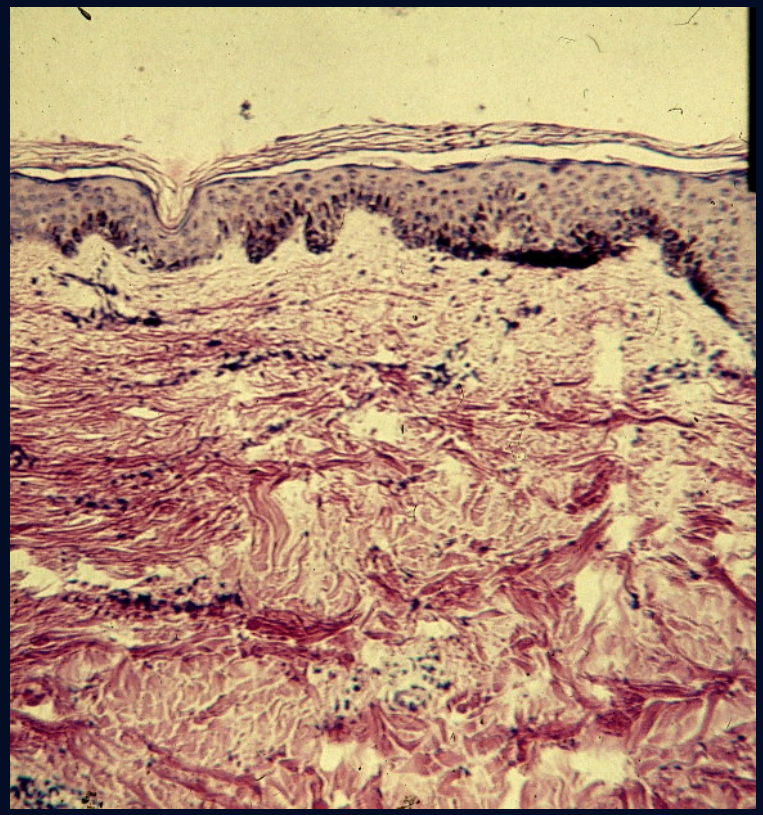

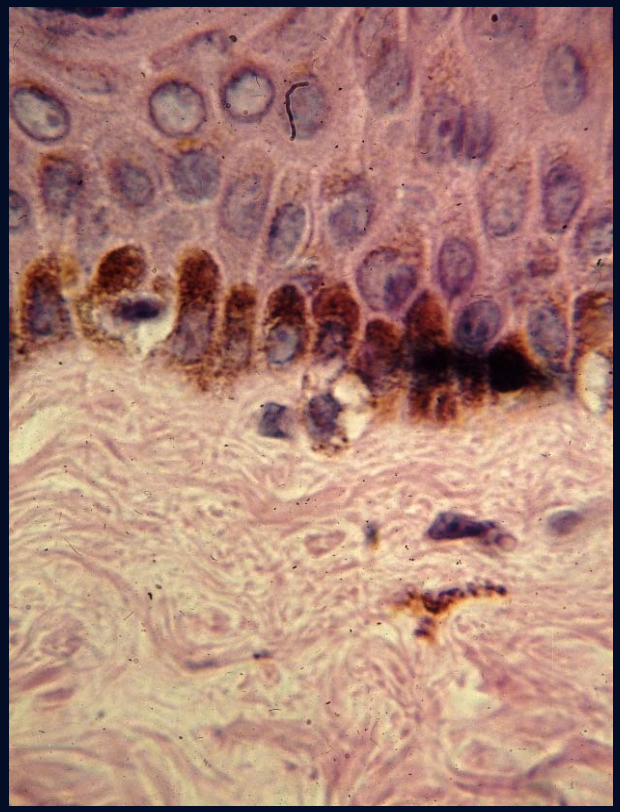

LENTIGO SIMPLEX

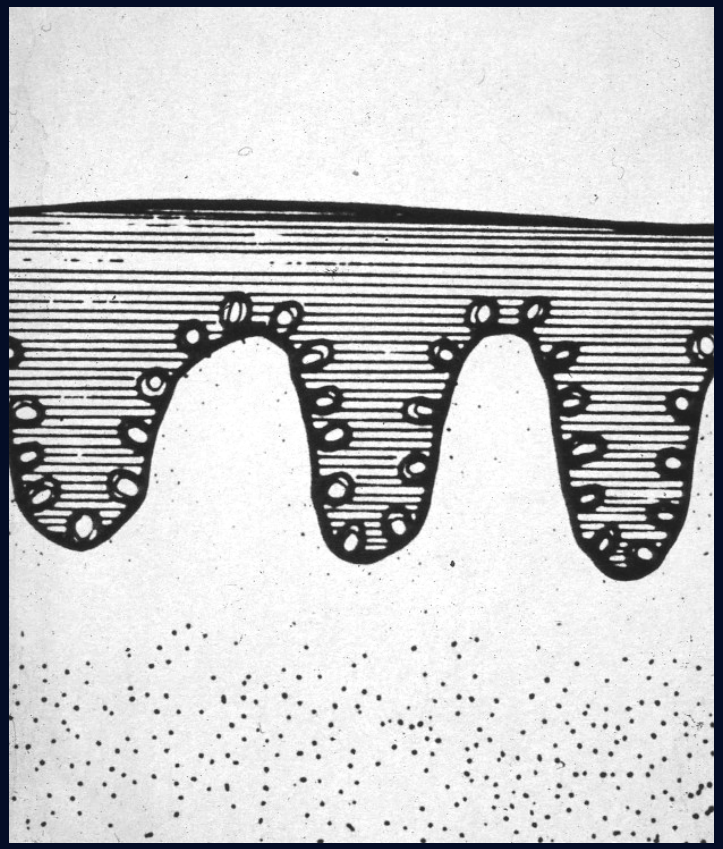

LENTIGO SOLARIS

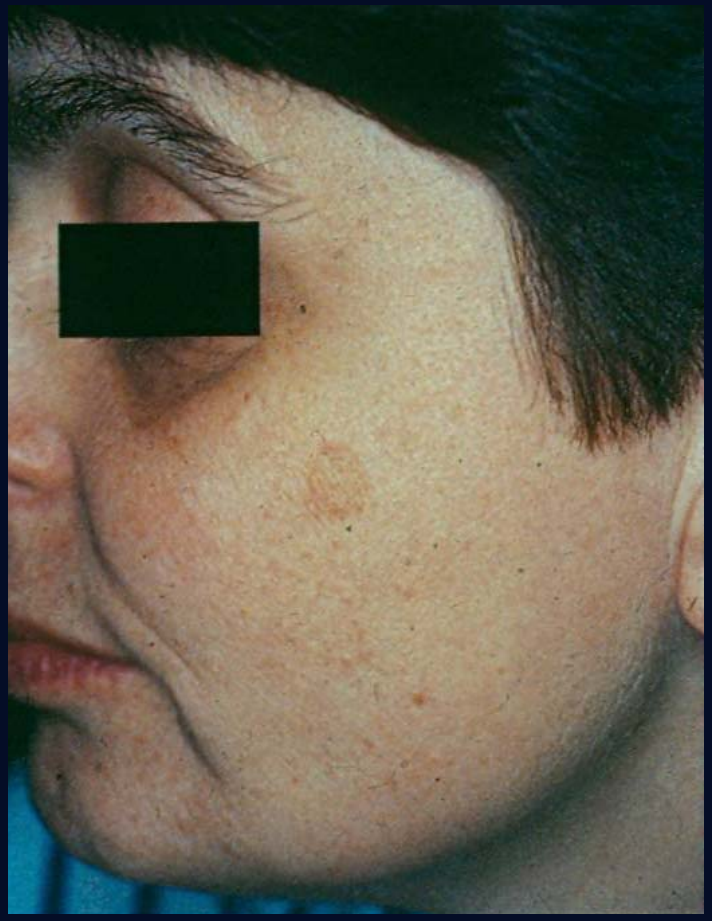

LENTIGO SOLARIS

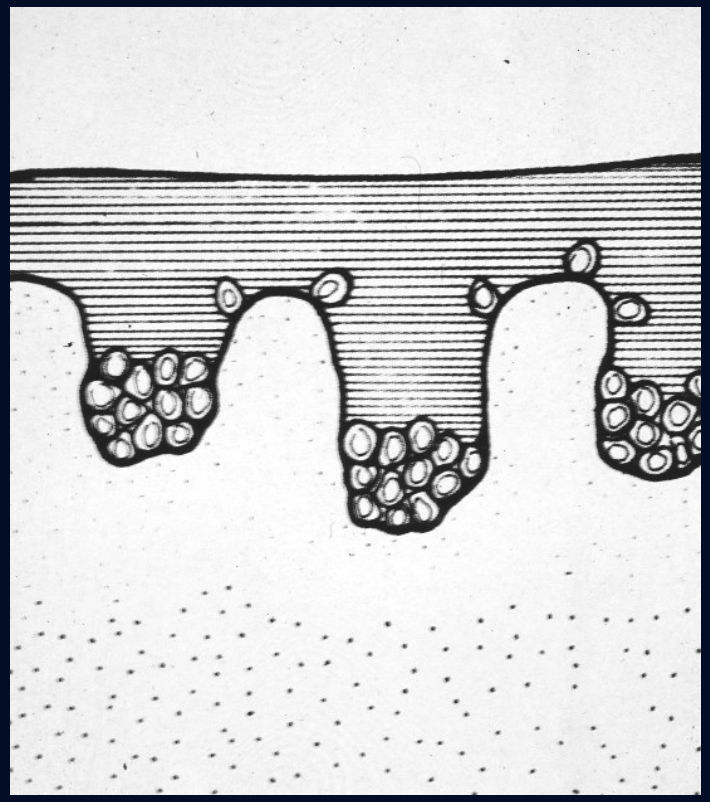

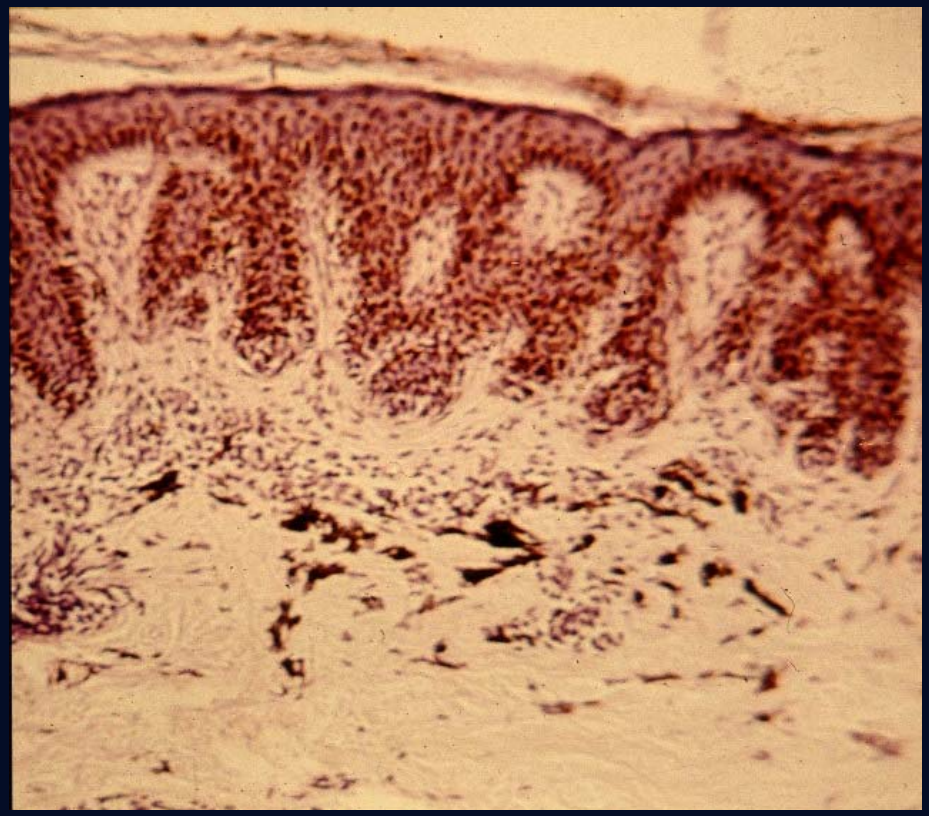

NAEVUS

- JUNCTIONAL
- COMPOUND
- DERMAL

JUNCTIONAL NAEVUS

JUNCTIONAL NAEVUS

COMPOUND NAEVUS

COMPOUND NAEVUS

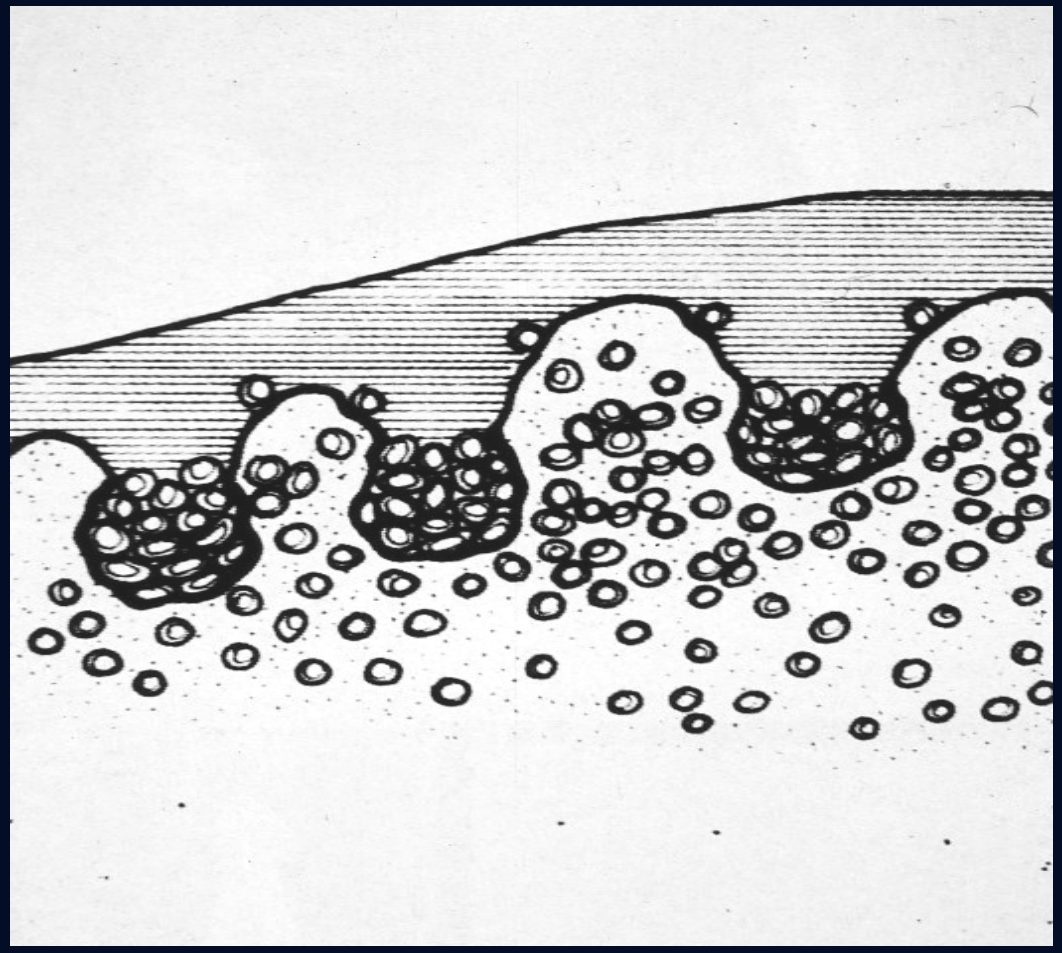

DERMAL NAEVUS

DERMAL NAEVI

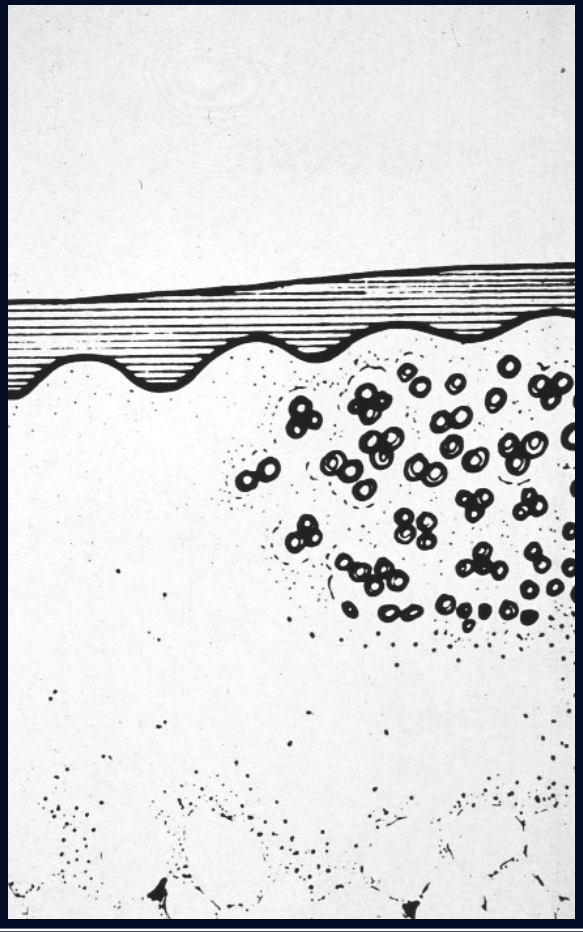

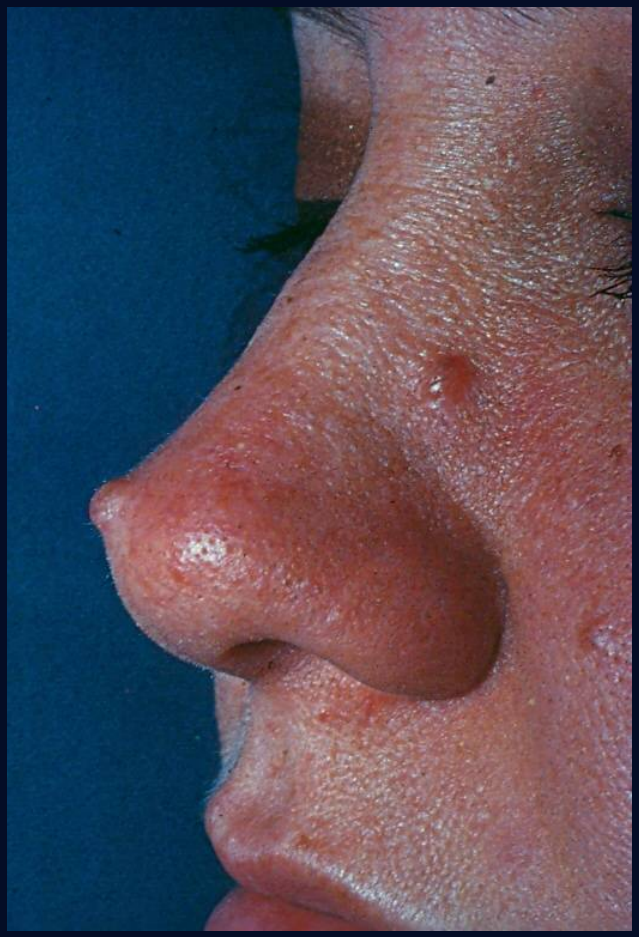

PARTICULAR NAEVI

- BLUE NAEVUS
- HALO NAEVUS
- DYSPLASTIC NAEVUS
- CONGENITAL NAEVUS
- SPITZ NAEVUS
- RECURRENT NAEVUS

BLEU NAEVUS

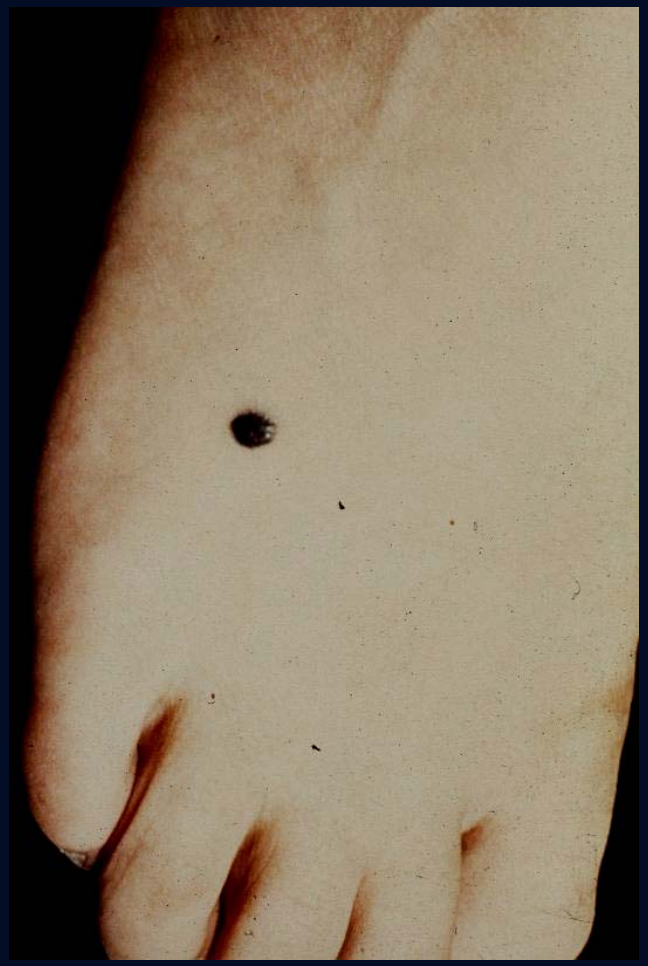

HALO NAEVI

SPITZ NAEVUS

PSEUDO-MELANOMA ACKERMANN

RECURRENT NAEVUS

DYSPLASTIC NAEVUS
risk marker for MM

- 2-5% Normal population (familiar/sporadic)
- after puberty (de novo or previous stable nevus)
- few → > 100 lesions
- trunk, extremities, also unexposed areas (scalp, buttocks, groin, female breasts)

DYSPLASTIC NAEVI

familiar

DYSPLASTIC NAEVI

sporadic

DYSPLASTIC NAEVI

CONGENITAL NAEVUS

CONGENITAL NAEVI

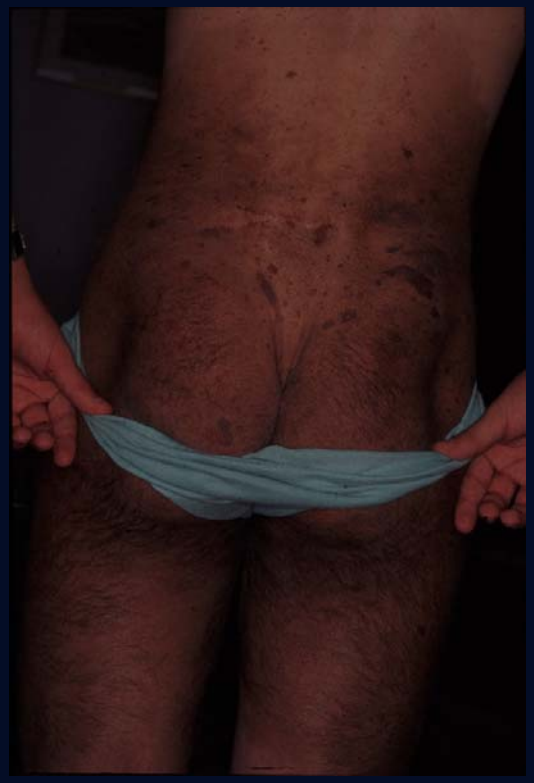

GIANT NAEVI

SKIN CANCER ↑

i.e. USA: 1 MILLION PER YEAR
excl. MALIGNANT MELANOMA

INCIDENCE IN YOUNGER PEOPLE ↑

A CENTURY OF DIFFERENCES

A CENTURY OF DIFFERENCES

SUN

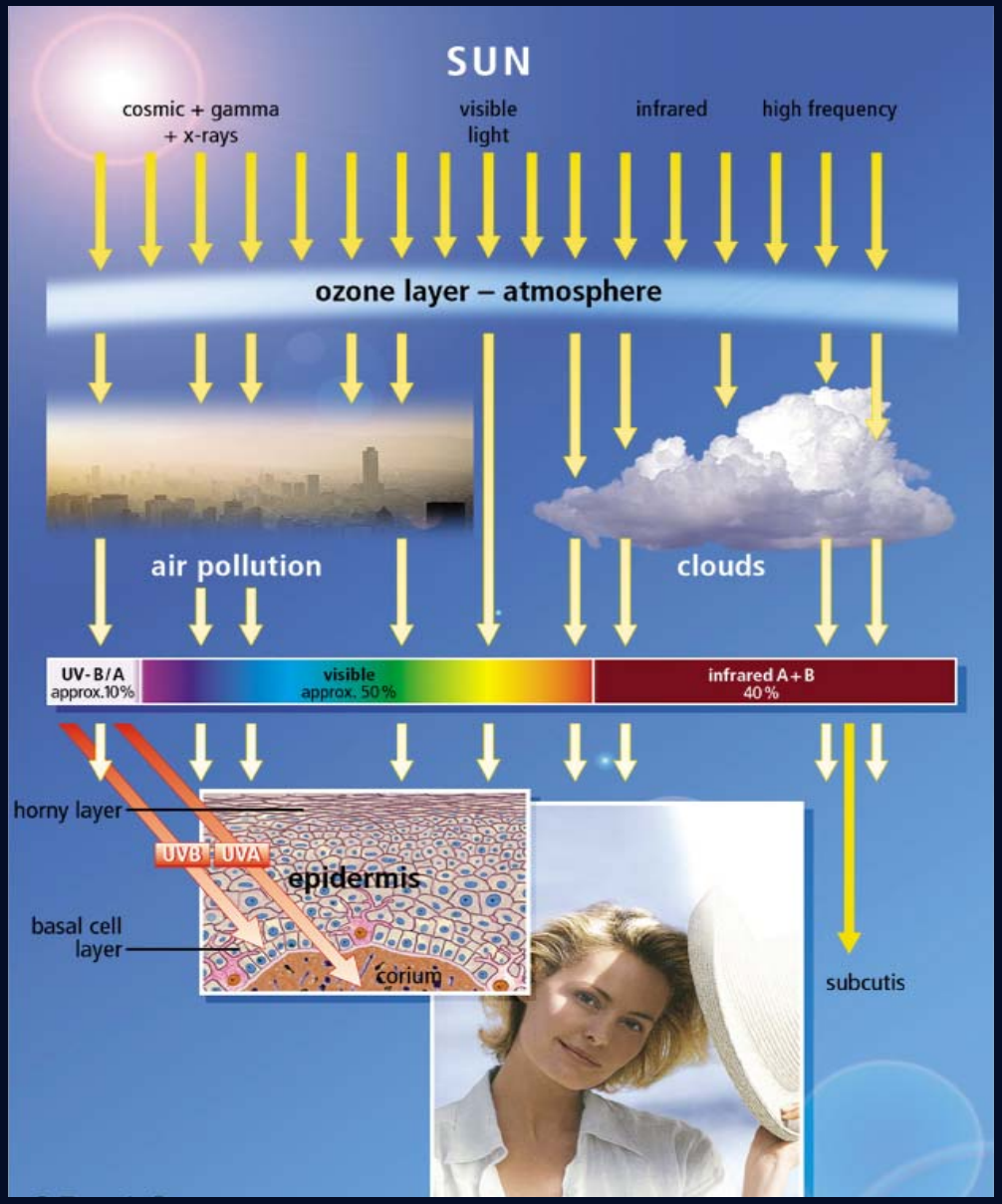
SUN
cosmic + gamma
+ x-rays
visible
light
infrared
high frequency
ozone layer – atmosphere
air pollution
clouds
UV-B/A
approx.10%
visible
approx. 50%
infrared A+B
40%
horny layer
UVB
UVA
epidermis
basal cell
layer
corium
subcutis

χ-stralen
UVA- UVB- UVC
x-stralen
OZON LAAG
IR
50%
ZICHTBAAR LICHT
40%
UVA-UVB
10%

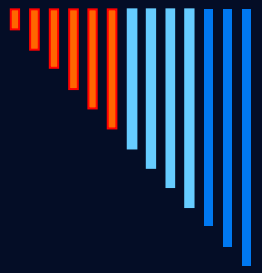

UVB

UVA

HUID

Vrije radicalen
DNA Beschadiging

↓

Huidkankers

Beschadiging
collageen

↓

Huidveroudering

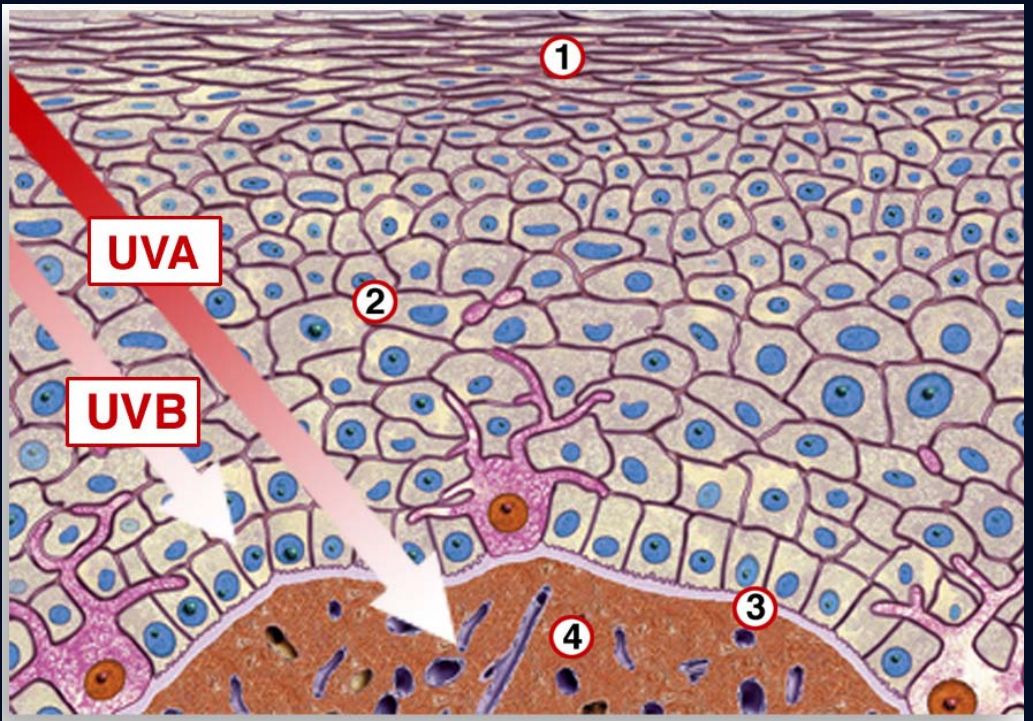

© Eucerin®

1 Stratum corneum
2 Epidermis
3 Basal layer
4 Dermis

INCIDENCE OF SKIN CANCER

- **Globally, WHO estimate up to 3 million non-melanoma skin cancers and 130,000 melanomas occur each year**
- **Estimated annual skin cancer cases (US):**

Basal Cell Carcinoma (>1 million):
most common, may be locally destructive, rarely metastasizes

Squamous Cell Carcinoma (>300,000):
rarer, but can metastasize

Melanoma (>53,000):
most aggressive, increasing in incidence

Genetic Basis of Skin Cancer

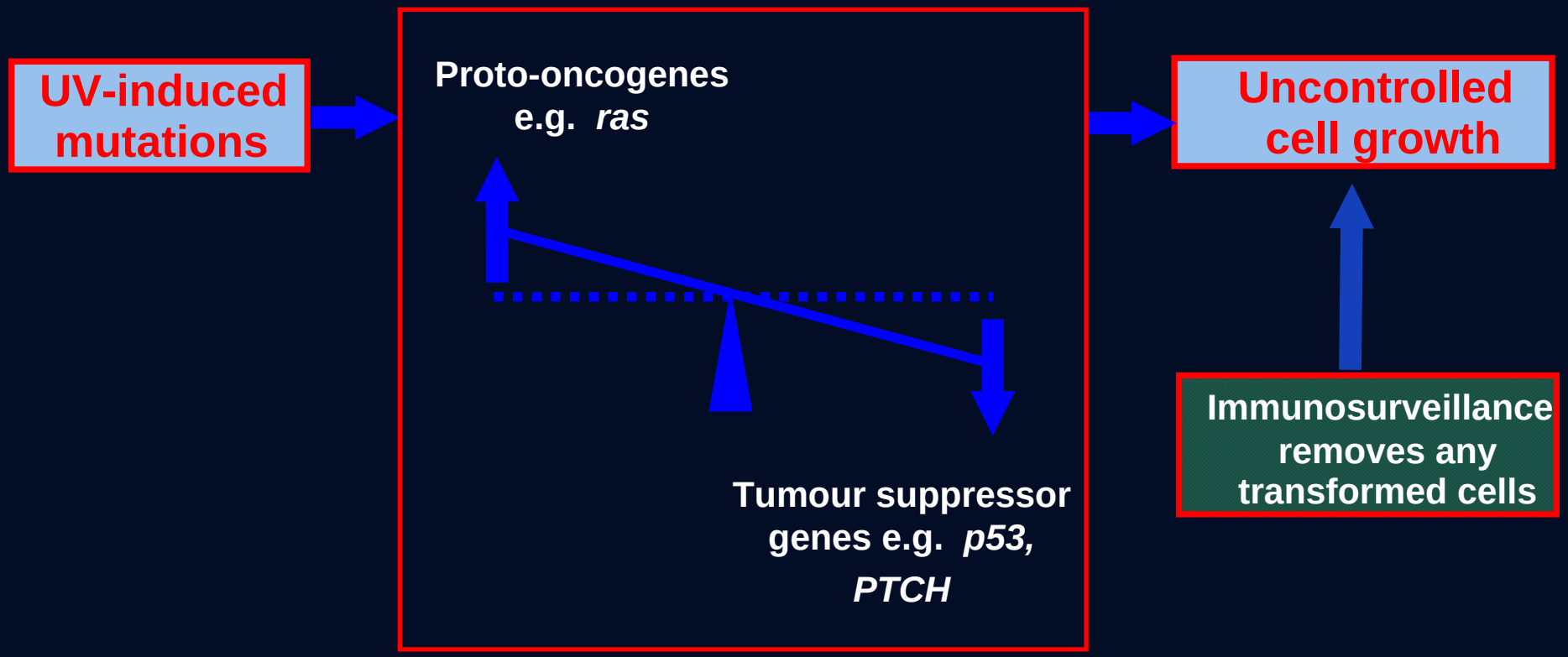

DNA Repair Process and Apoptosis Control Malignant Transformation

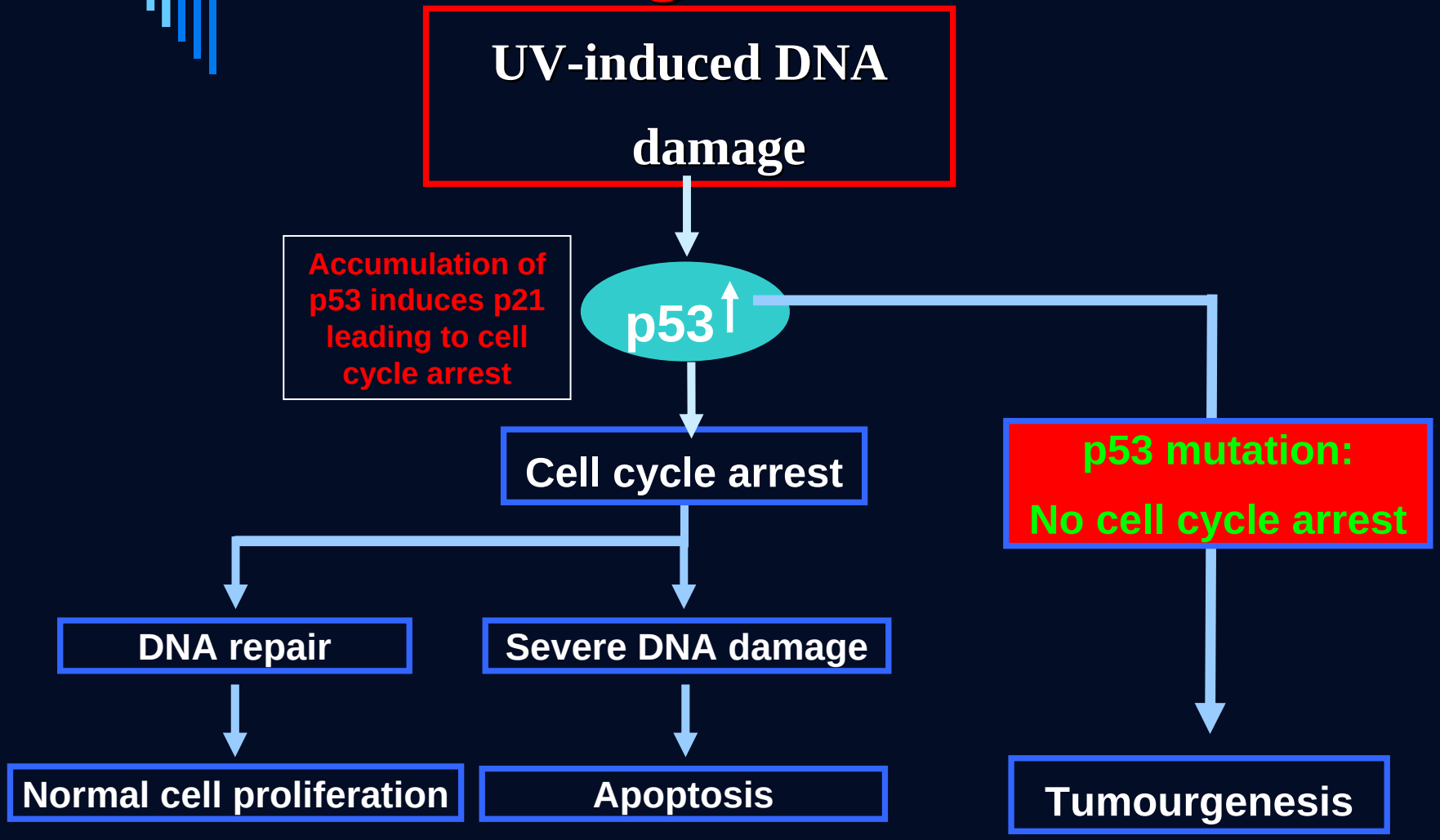

UV GEÏNDUCEERDE HUIDBESCHADIGING

↓ ACUUT

↓ CHRONISCH

Schadelijke effecten UV

Onmiddellijke
- zonnebrand
- polymorfe lichteruptie
- photodermatitis
- Mallorca acne
- ↓immuniteit (herpes)

Laattijdige
- huidveroudering
- precancerosen
- huidkankers
  - epitheliomen
  - melanoom

U.V. induced skin damage

acute

chronic

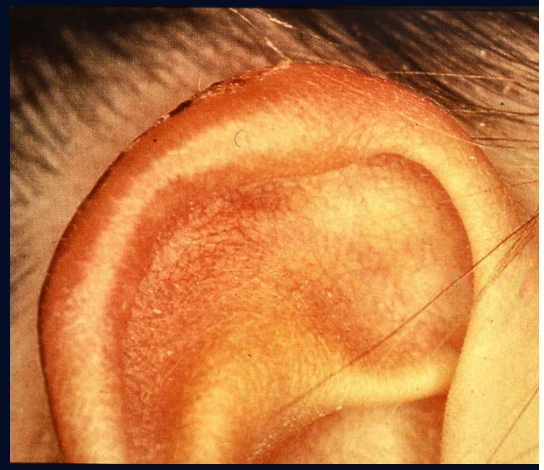

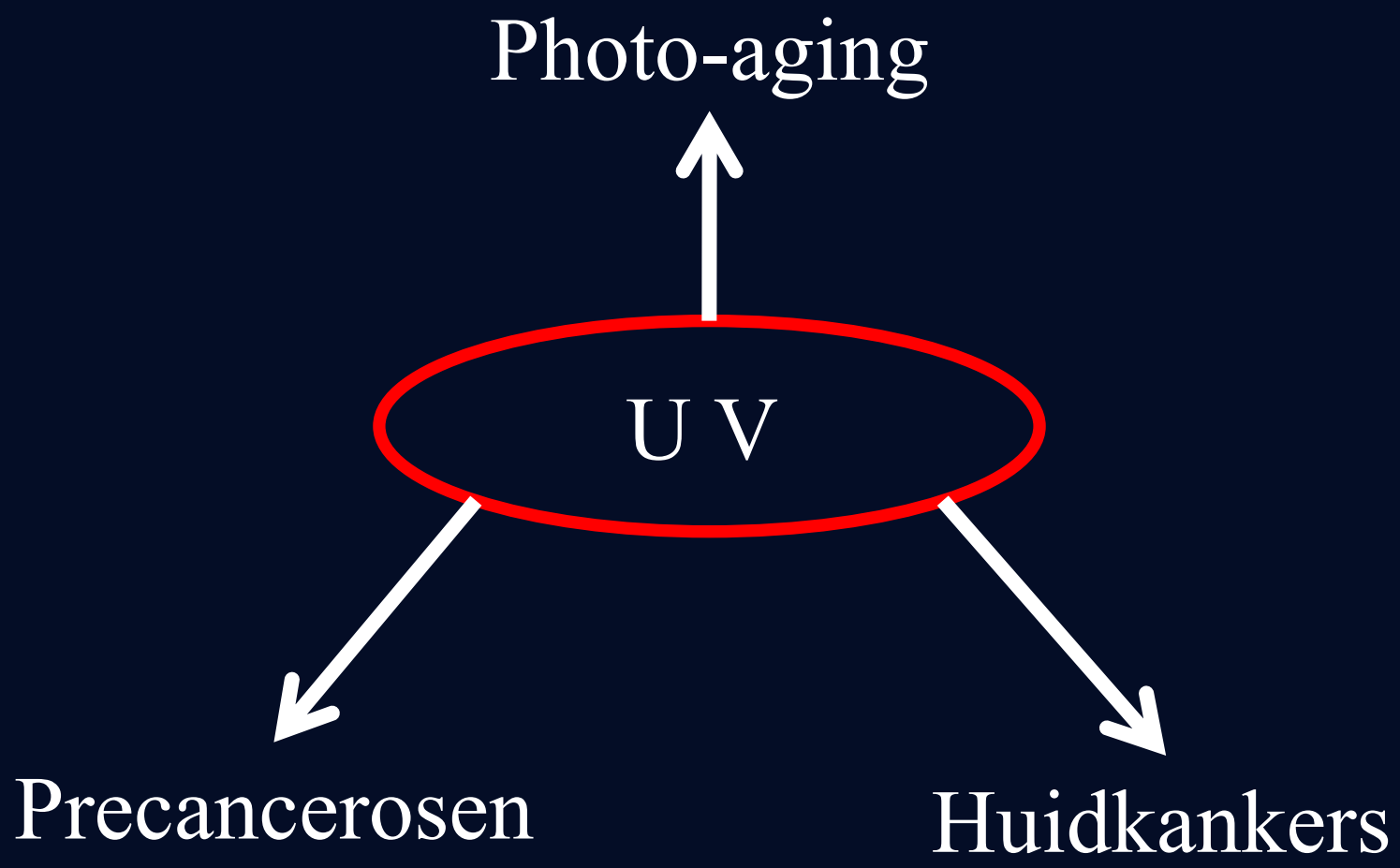
Photo-aging
U V
Precancerosen
Huidkankers

PHOTO-AGING

Photo-aging

↓

cutaneous carcinomas

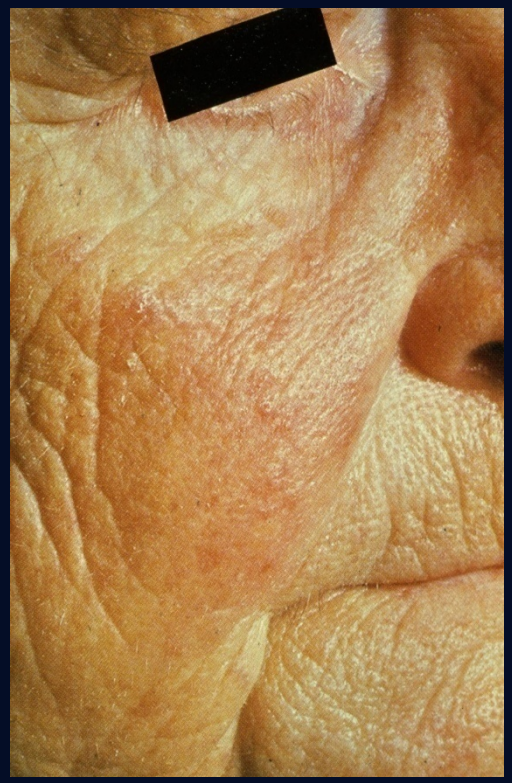

SOLAIRE LENTIGO'S

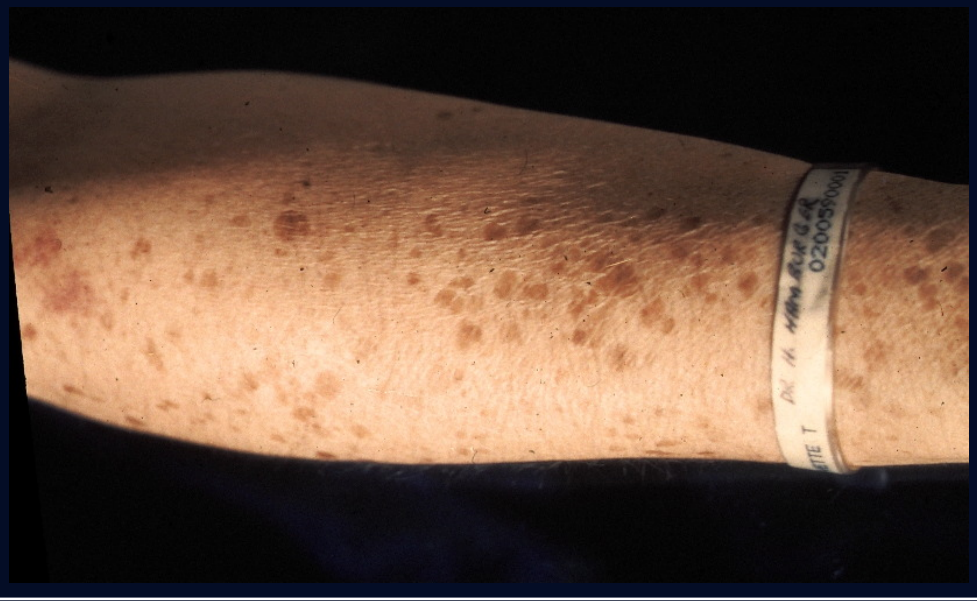

PRECANCEROUS LESIONS

Actinic keratosis

Actinic keratosis

Cornu cutaneum

Lentigo Maligna

MALIGNANT SKIN TUMOURS

Dr. ARLETTE DE CONINCK UZ Brussel

3 April 2008

SKIN CANCER

CARCINOMA

SARCOMA

MELANOMA

CARCINOMA

↓ ↓ ↓

Basalcell **Merkel cell** **Squamouscell**

SKIN CARCINOMA

SCC

BCC

LOW MALIGNANCY

SKIN CARCINOMA

↓

LOCO-REGIONAL INVASION

↓

MUTILATIONS

Basal Cell Carcinoma

SUNBURN IN CHILDHOOD

EXCESSIVE RECREATIONAL EXPOSURE FIRST TWO DECADES

BASAL CELL CARCINOMA

PALE SKIN

FRECKLING

ONCOLOGIC

EFFICIENCY

COSMETIC

MINIMAL SEQUELLAE

FUNCTIONAL

IDEAL TREATMENT

Goals of Treatment

- complete eradication of the tumour
- highly desirable: avoid recurrences as these are more difficult to retreat
- risk of recurrence after treatment depends on:
  - histological type (patterns of infiltration, sclerosis, or multifocality)
  - localization (mid-face, ear, scalp, and forehead have the highest risk of recurrence)
  - size of primary tumour (>6 mm in diameter)
  - medical history of a previous BCC

Treatment Modalities for Basal Cell Carcinoma

- Surgical Excision
- Cryosurgery
- Curettage and Electrodesiccation
- Micrographic Surgery

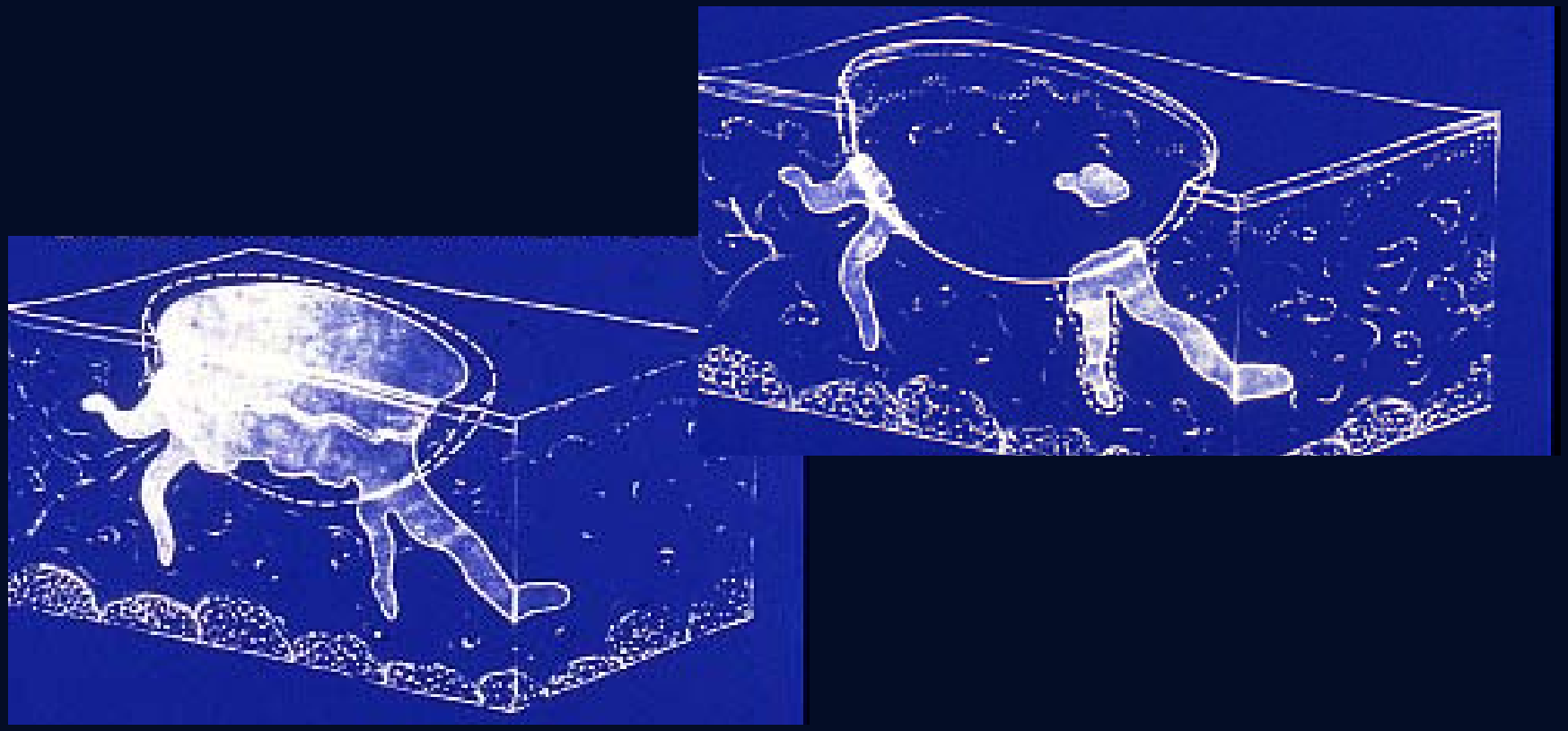

efficiency of treatment

↓

recurrence

CLINICAL AND HISTOLOGICAL CHARACTERISTICS

YOUNG PEOPLE

LOCALISATION

MICROGRAPHIC SURGERY FOR BCC

DIAMETER

RECURRENCE

INCOMPLETE RESECTION

RECURRENT BCC

GREATER SUB-CLINICAL EXTENSIONS

LARGER SCAR

CLINICAL TYPES

- NODULO-ULCERATIVE BCC
- NODULO-CYSTIC BCC
- MULTIFOCAL (SUPERFICIAL) BCC
- MORPHEA-LIKE (DIFFUSE, SCLEROSING) BCC
- PIGMENTED BCC

NODULAR BCC

ULCERATED BCC

NODULO-CYSTIC BCC

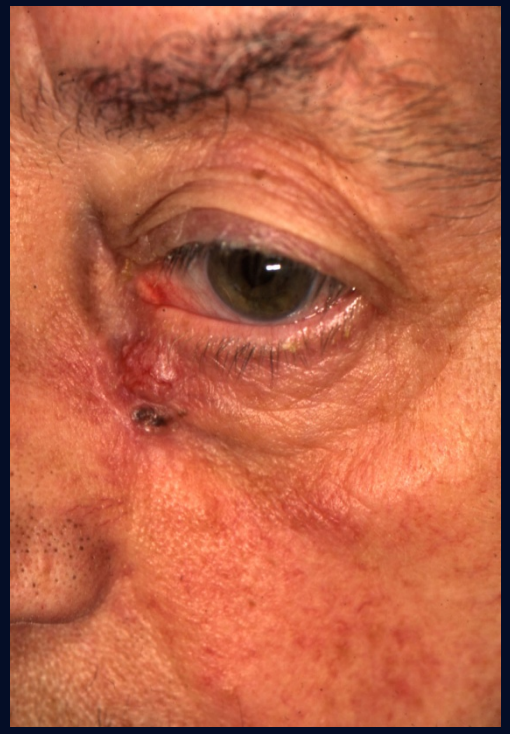

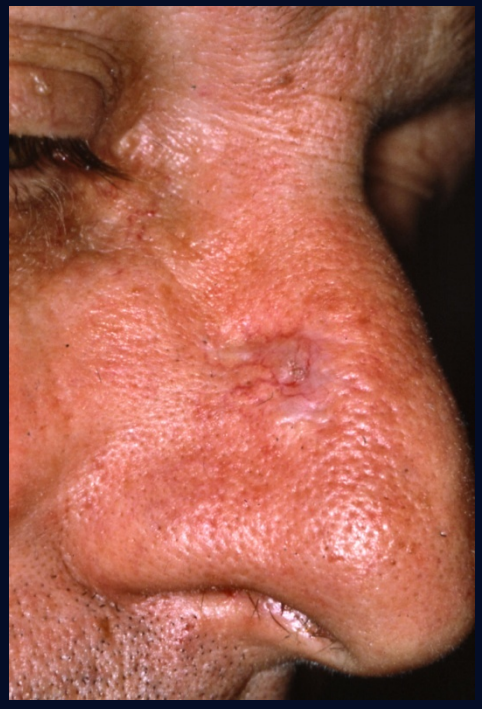

SUPERFICIAL MULTIFOCAL BCC

SCLERODERMIFORM BCC

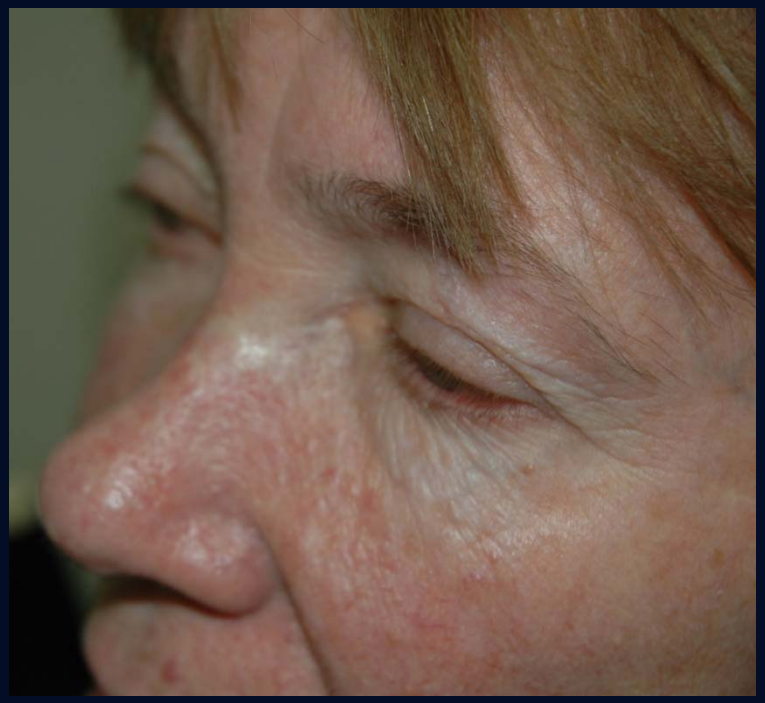

PIGMENTED BCC

NAEVUS SEBACEOUS & BCC

HISTOPATHOLOGISCHE TYPES

- SCLERODERMIFORM PATTERN
- MULTIFOCAL PATTERN
- METATYPICAL / BASOSQUAMOUS
- MICRONODULAR / MICROCYSTIC
- SOLID (NODULAR) PATTERN

HISTOLOGICAL TYPES

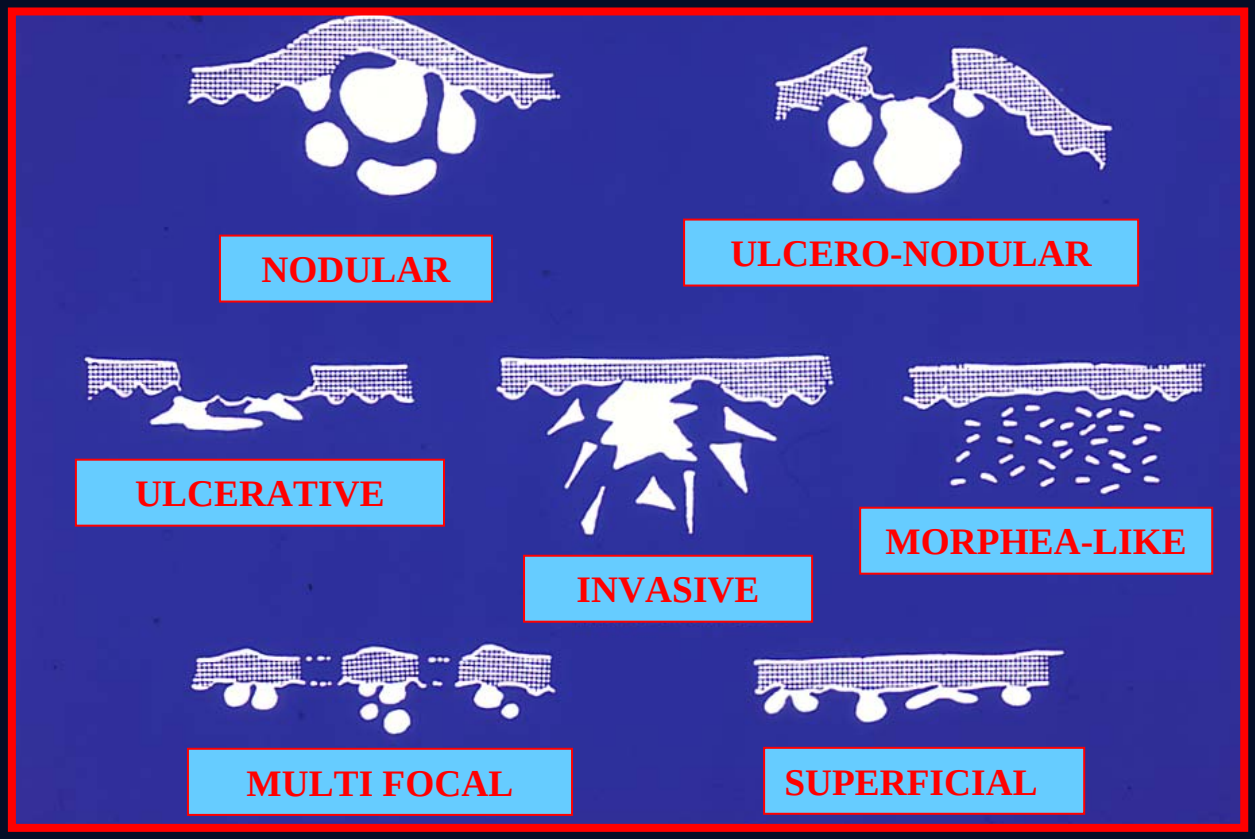

H - ZONE

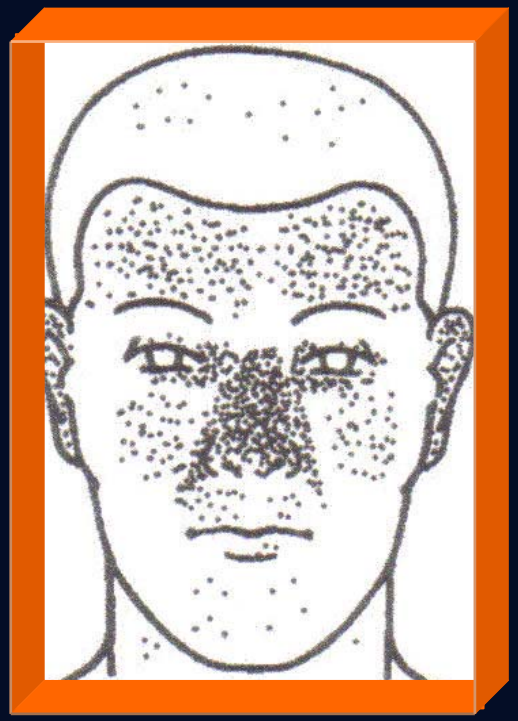

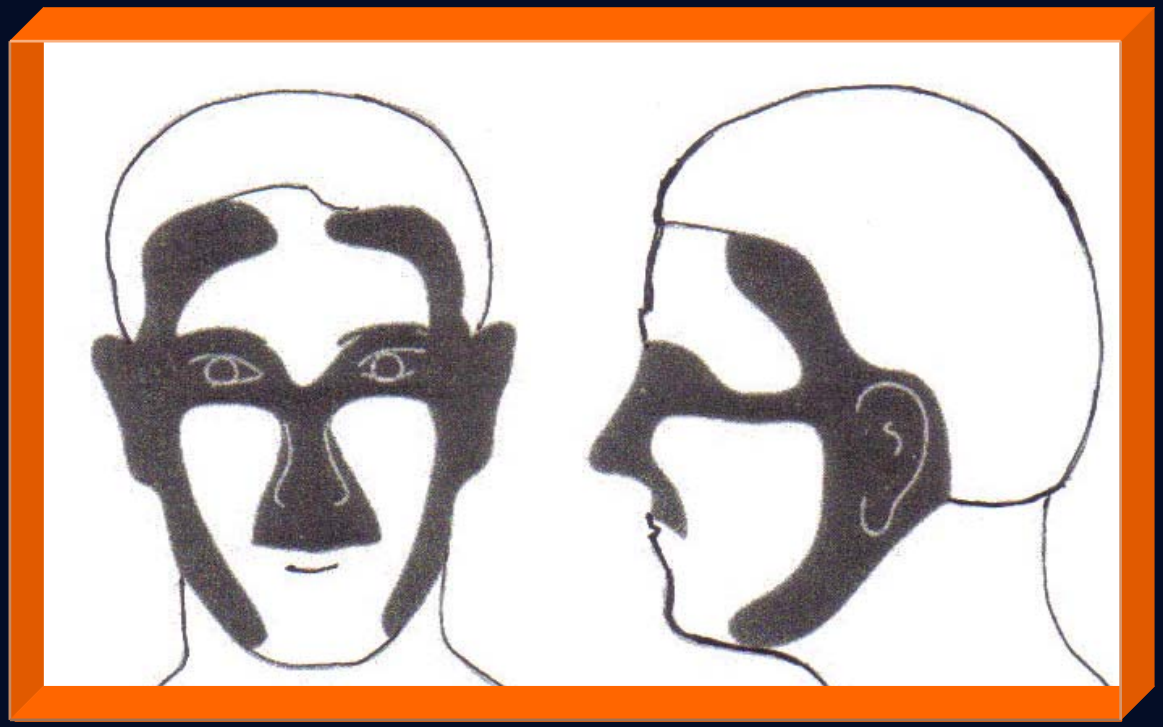

ONCOLOGIC

EFFICIENCY

COSMETIC

MINIMAL SEQUELLAE

FUNCTIONAL

IDEAL TREATMENT

MICROGRAPHIC SURGERY

MICROSCOPICALLY CONTROLLED SURGERY

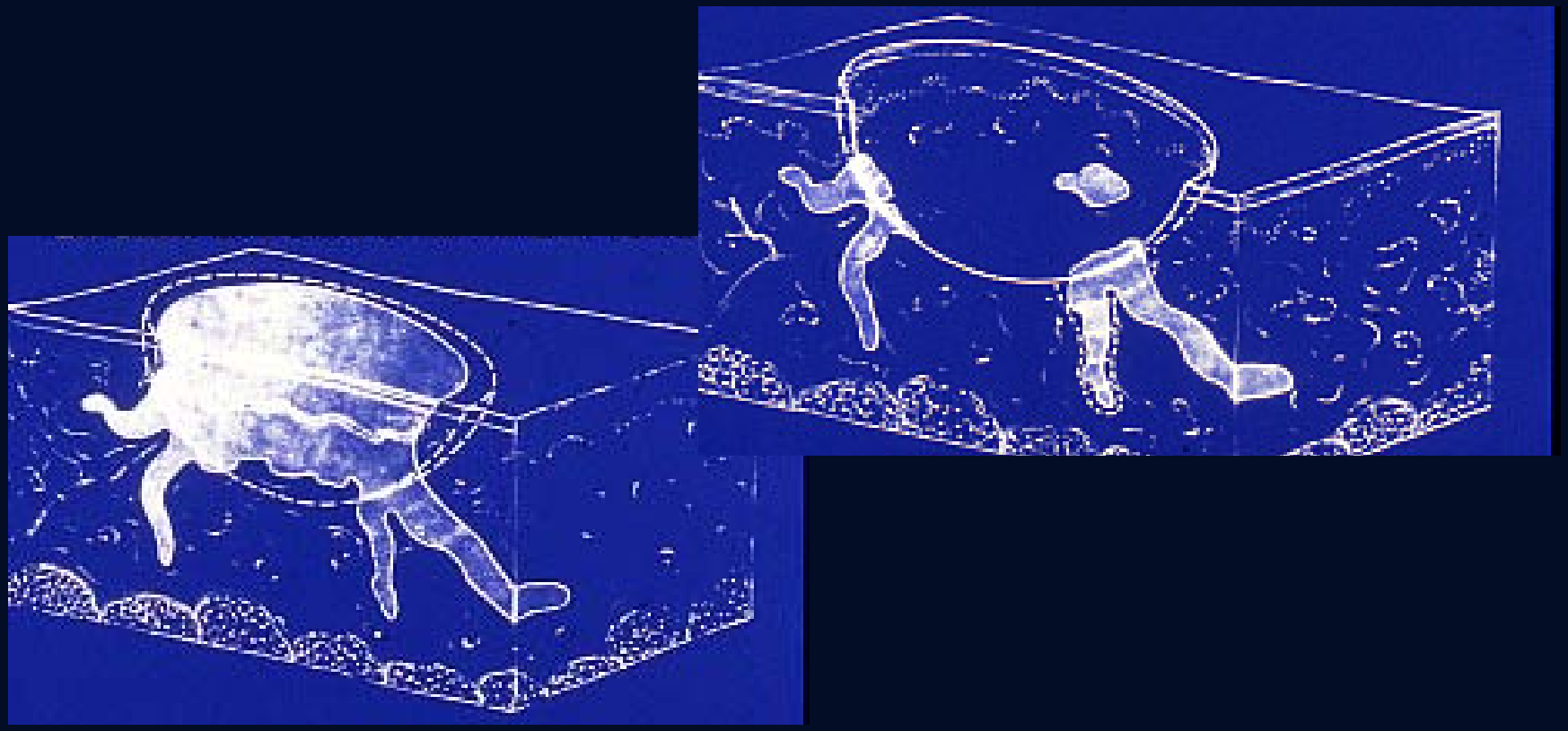

160 sections per 1 mm (6 µsections)

4.800 sections for a 3 cm specimen

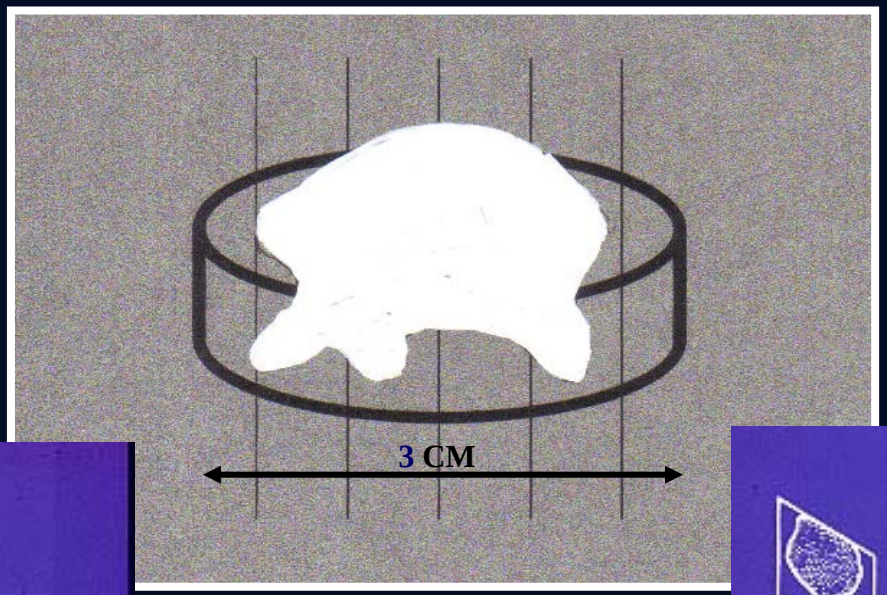

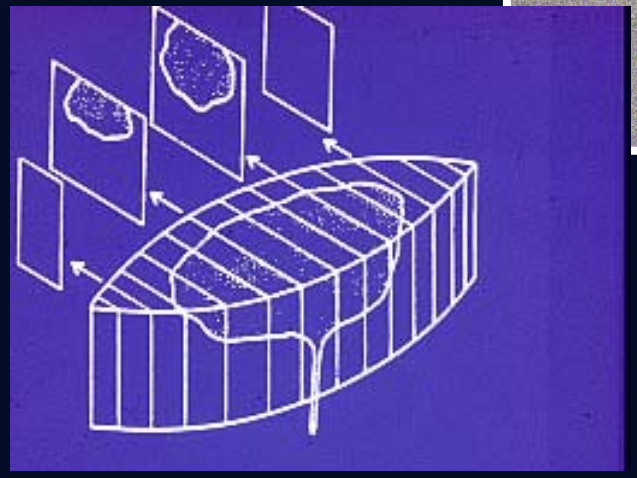



ADVANTAGES HORIZONTAL VERSUS VERTICAL SECTIONING

DEMONSTRATION
ALL CONTIGUOUS
TUMOR STRANDS

COMPLETE EVALUATION
ALL MARGINS WITH
REDUCED NUMBER OF
HISTOLOGICAL SECTIONS

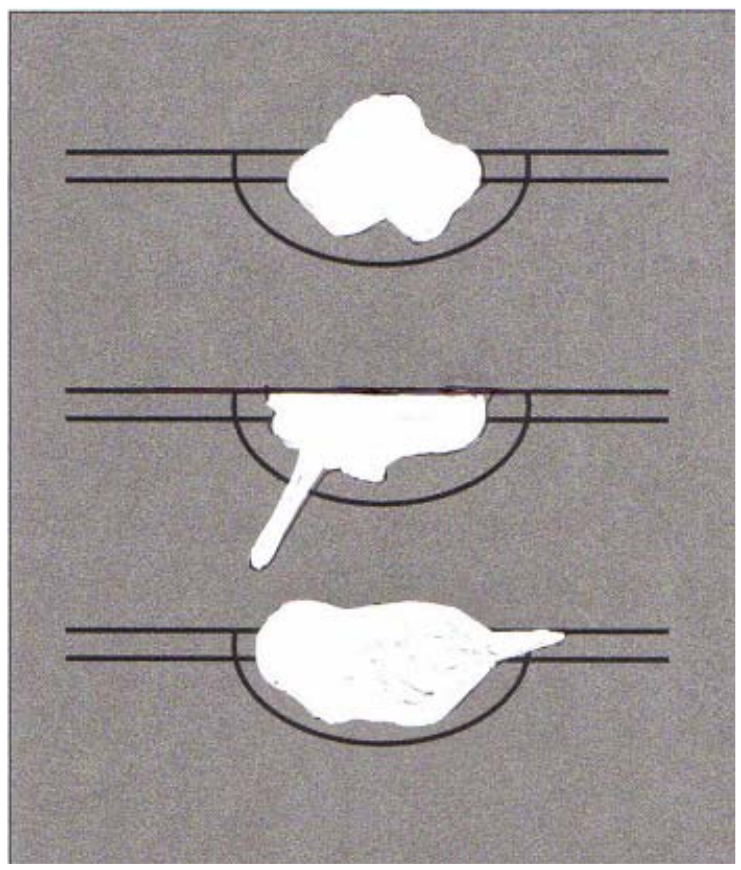

Different steps of Micrographic Surgery

ORGANISATION

- excision of the specimen
- tissue preparing for cryostat sectioning
- obtaining frozen horizontal slides
- slide review and interpretation
- additional stages → tumor free margins
- reconstruction

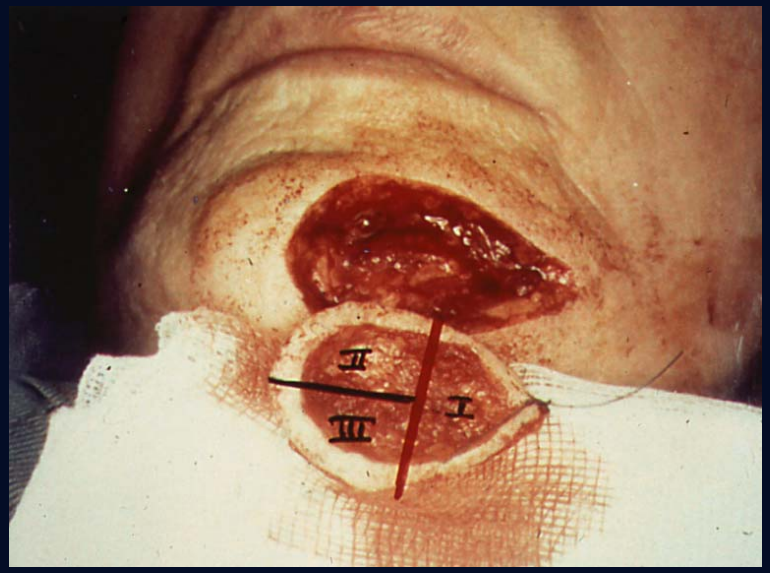
II
I
III

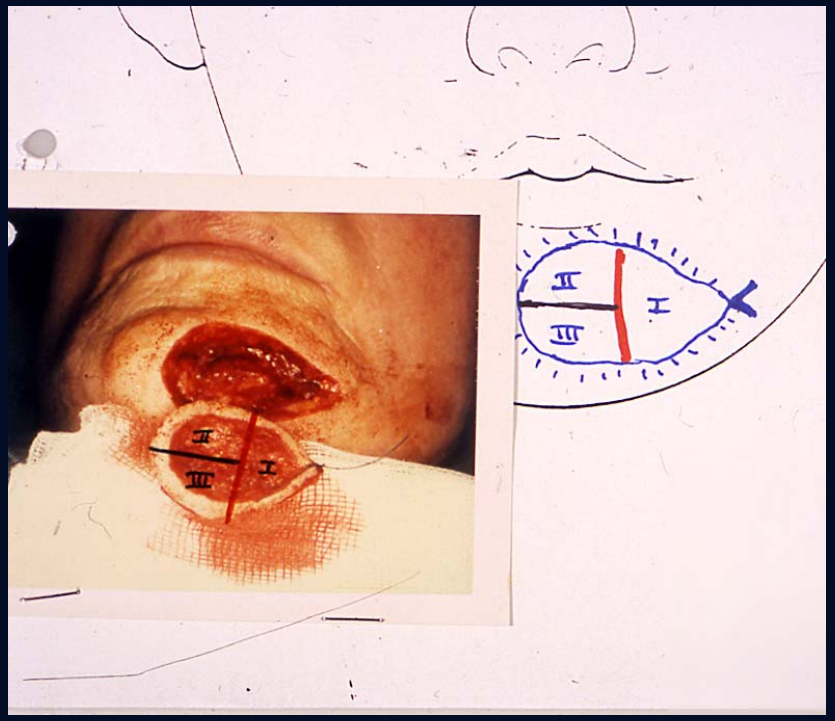

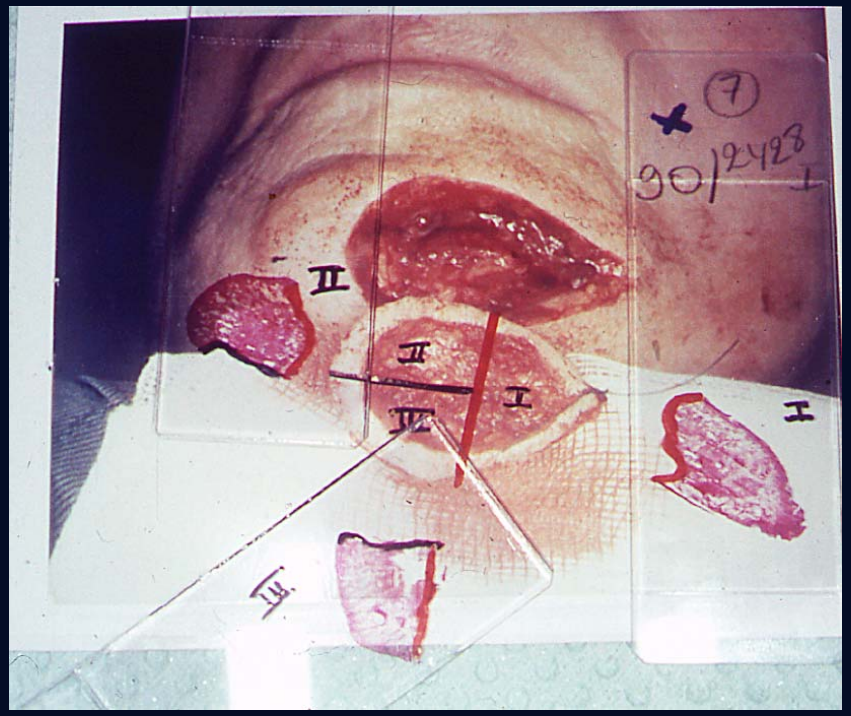
90/2428

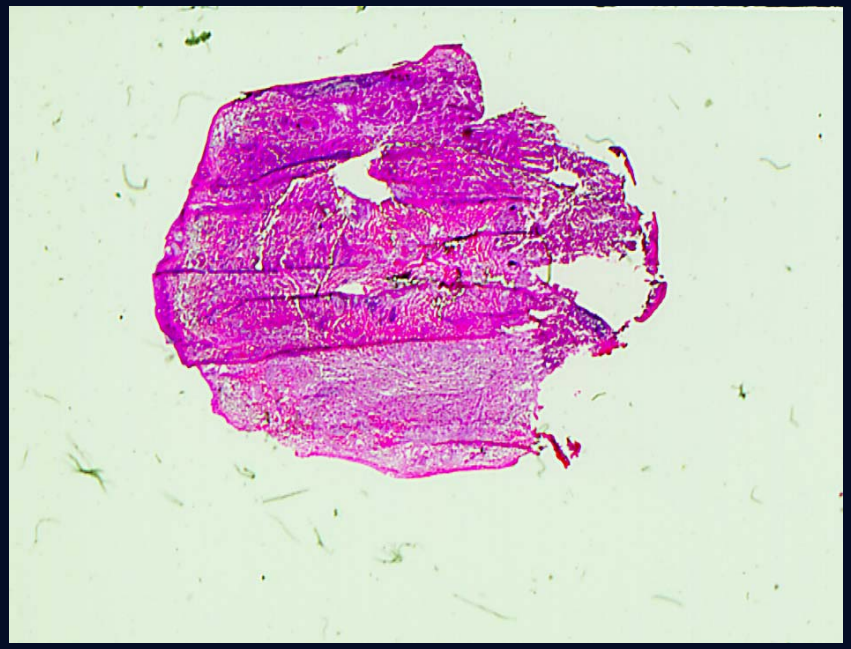

Number of excisions required with MGS to eradicate BCC

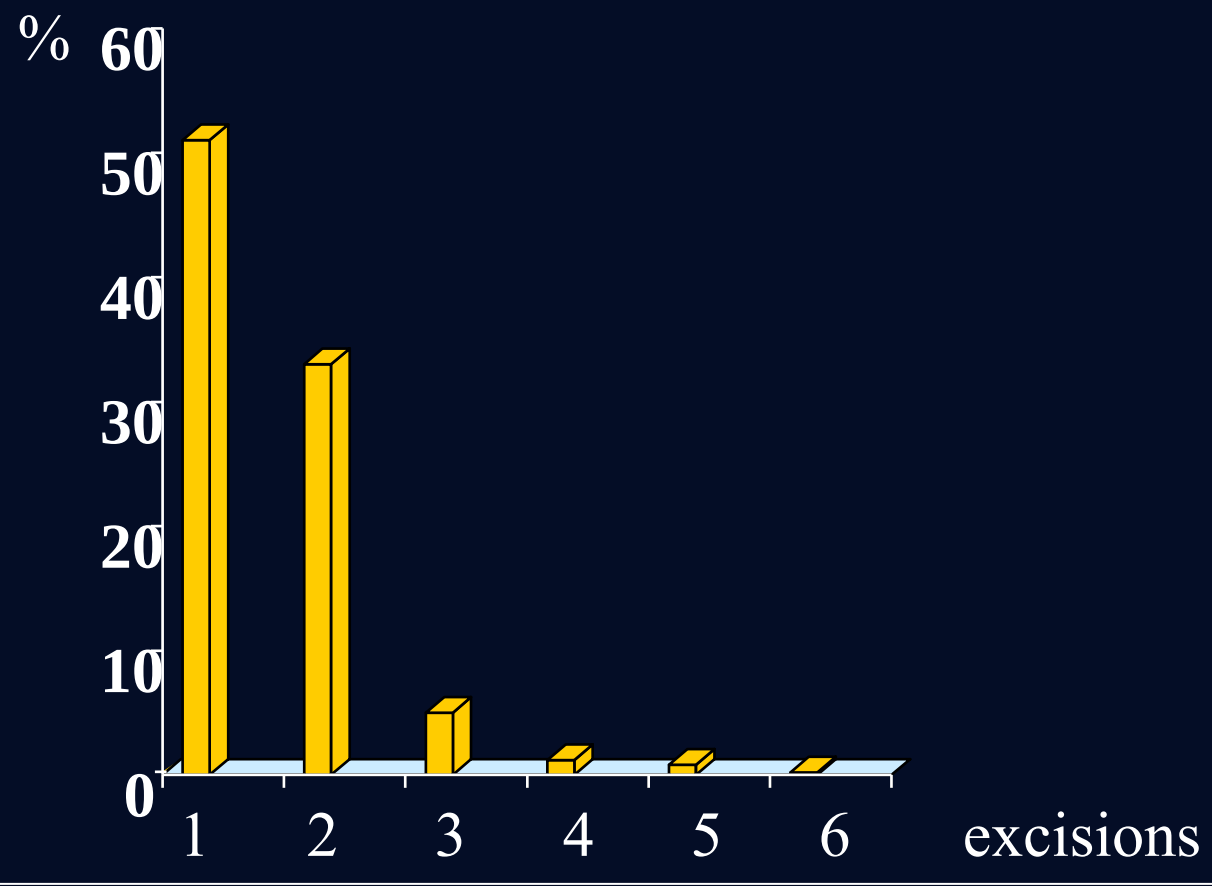

T. Winnock, D. Roseeuw , A. De Coninck, P. Dierickx, Skin Cancer 1996: 19-24

PROVEN BCC

- Primary BCC
  - < 2 cm
    - Well-defined, limited invasive
      - Outside H-zone
        - Depending on the skills of the physician
          - Surgical excision
          - Curettage + electrodesiccation
          - Cryosurgery
      - Inside H-zone → Micrographic Surgery
    - Ill-defined, aggressively invasive → Micrographic Surgery
  - >2 cm → Micrographic Surgery
- Recurrent BCC → Micrographic Surgery

RECURRENT BCC

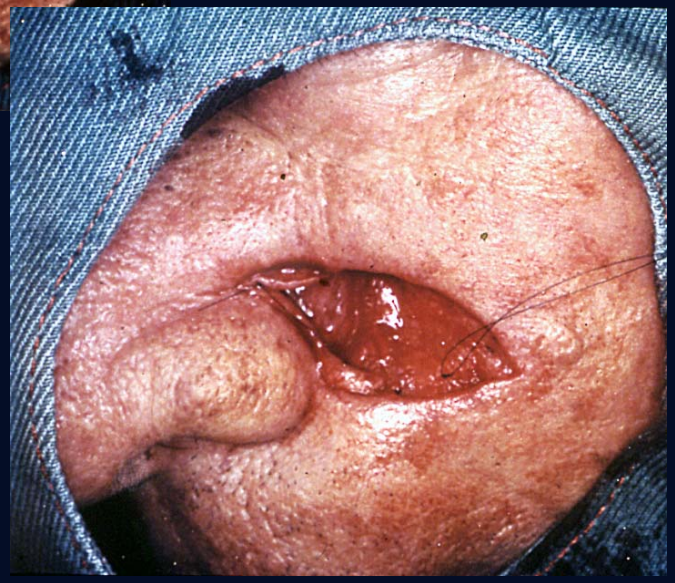

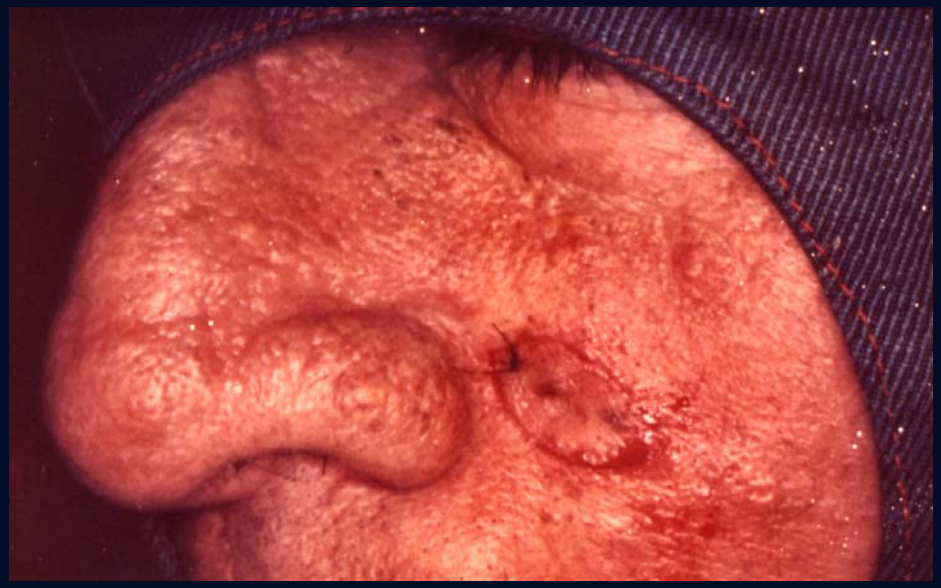

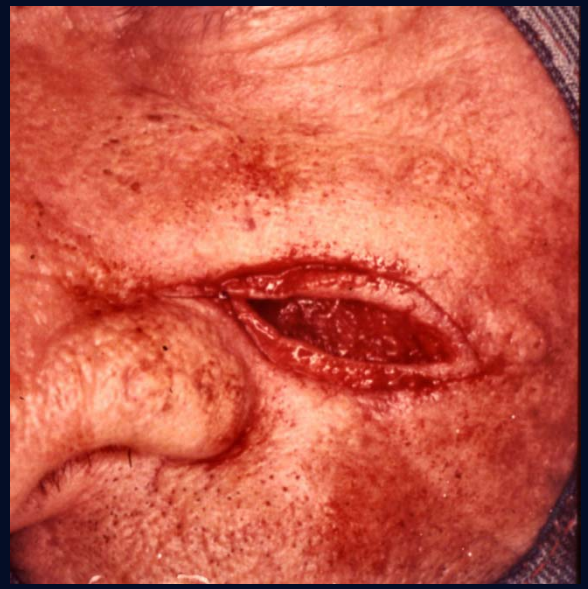

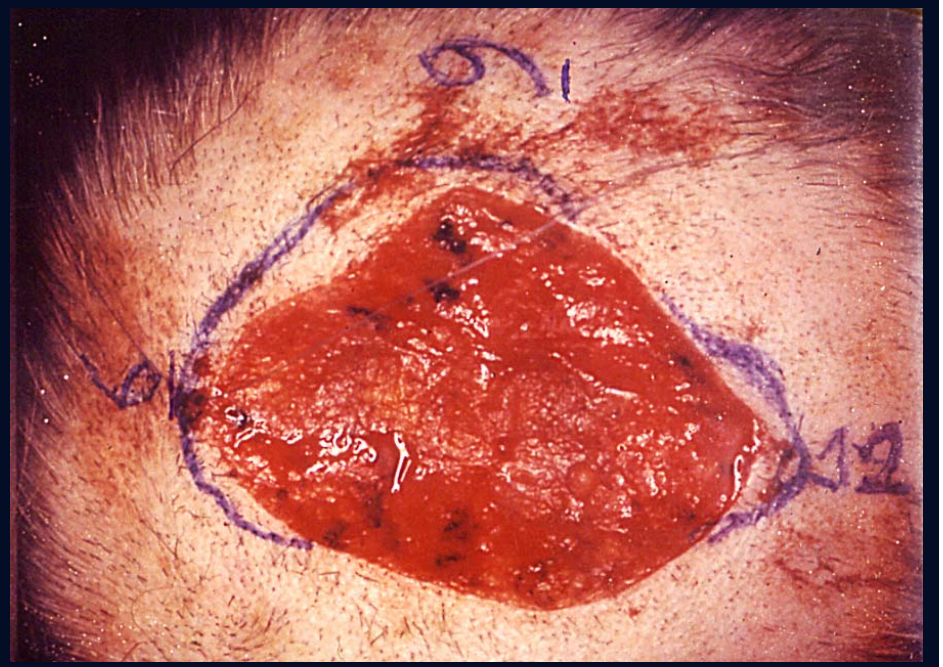

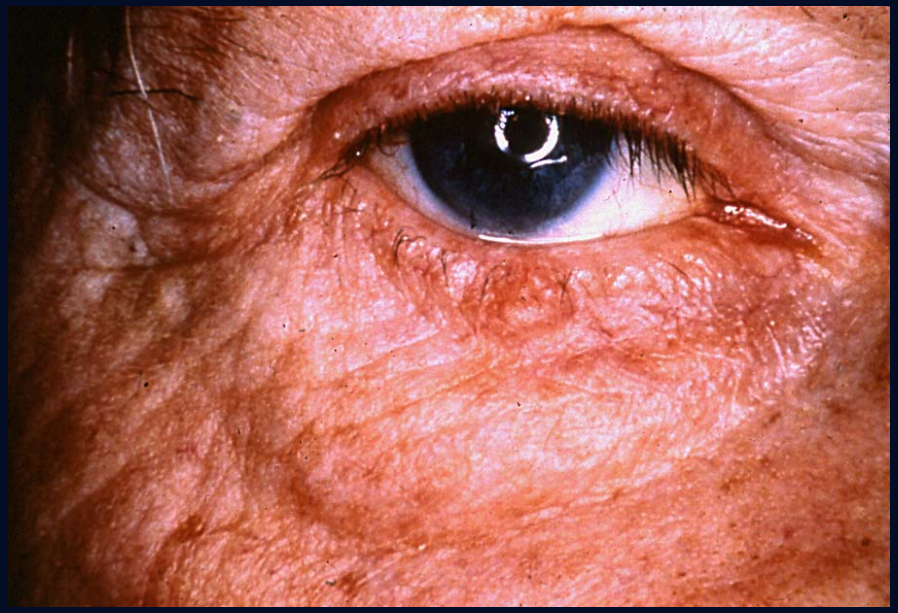

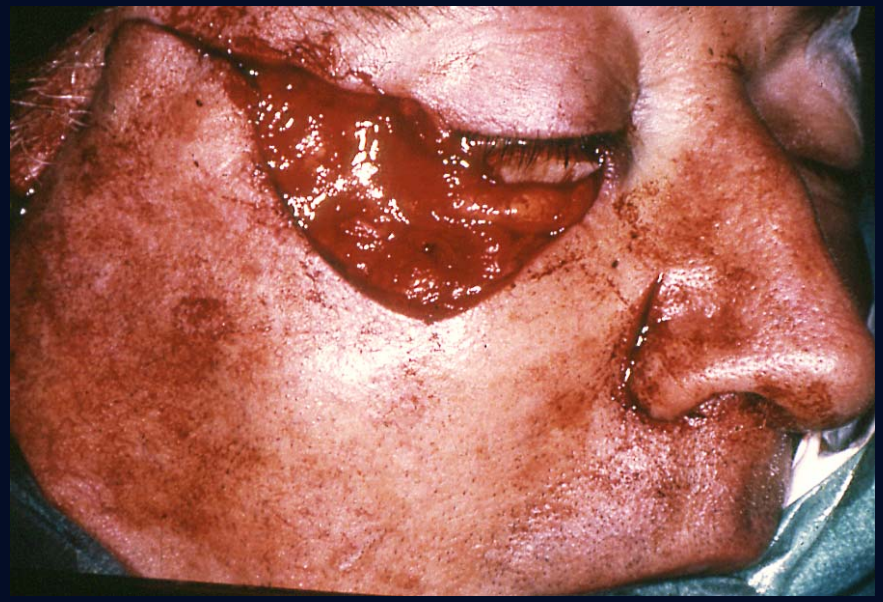

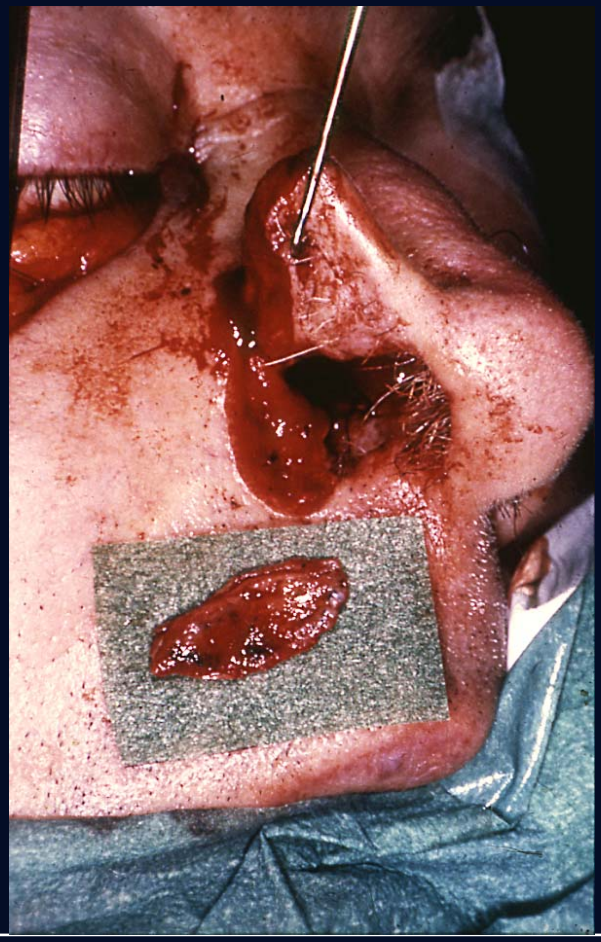

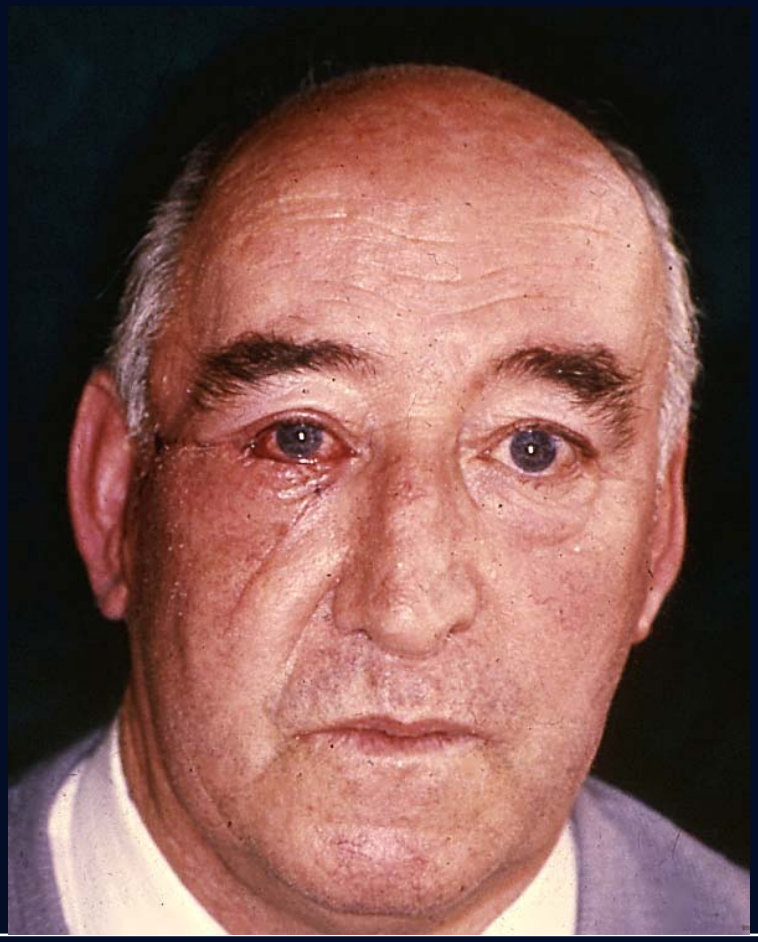

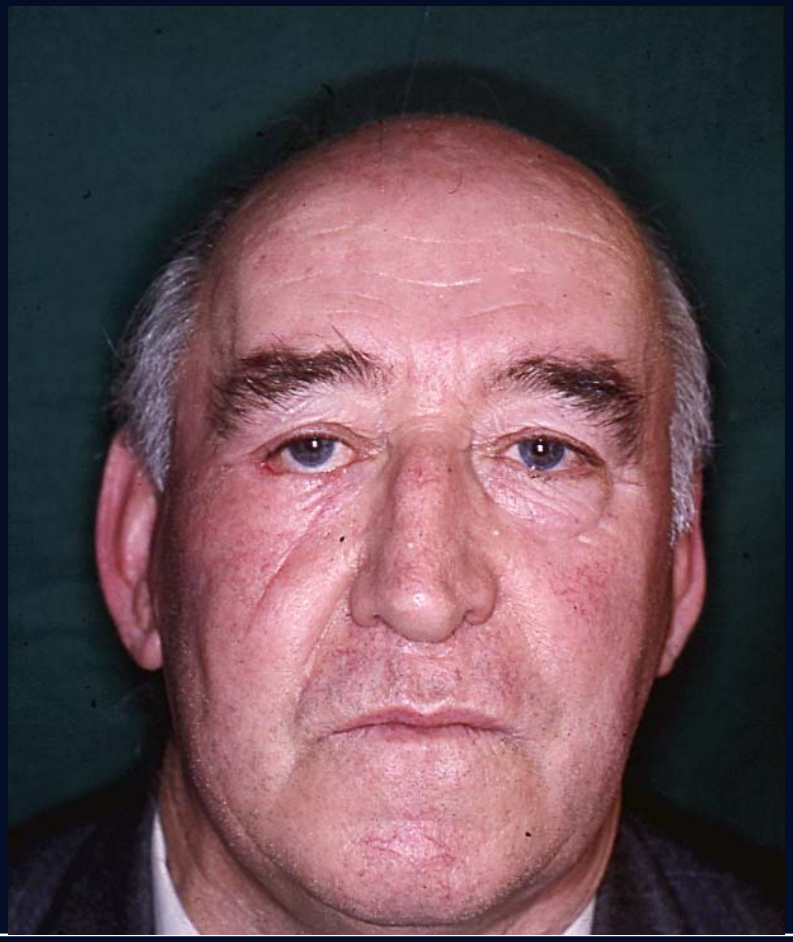

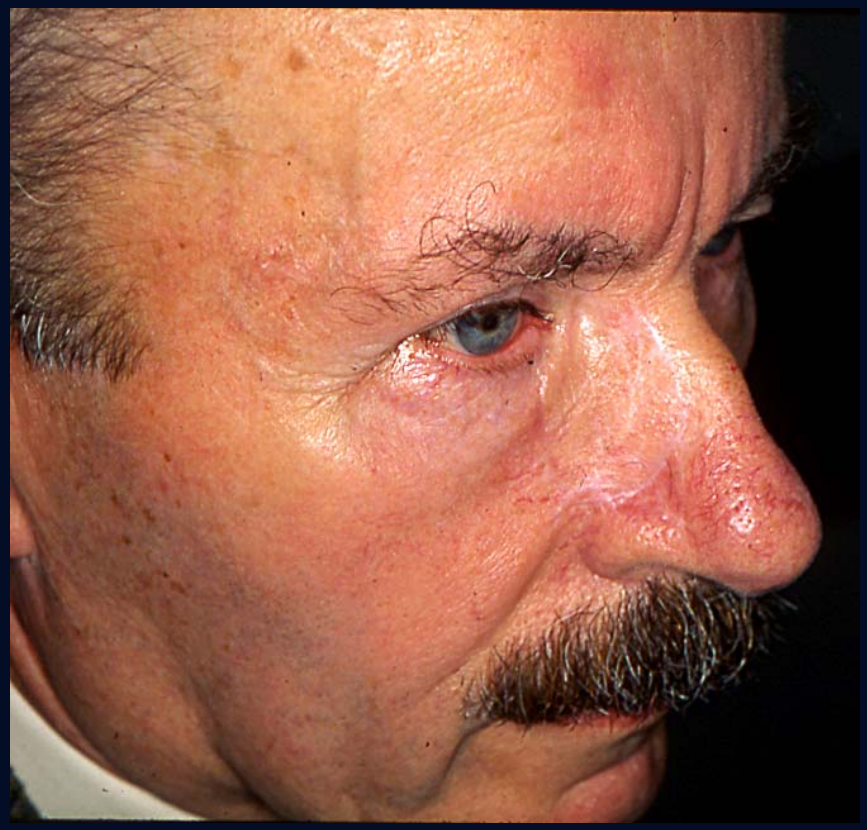

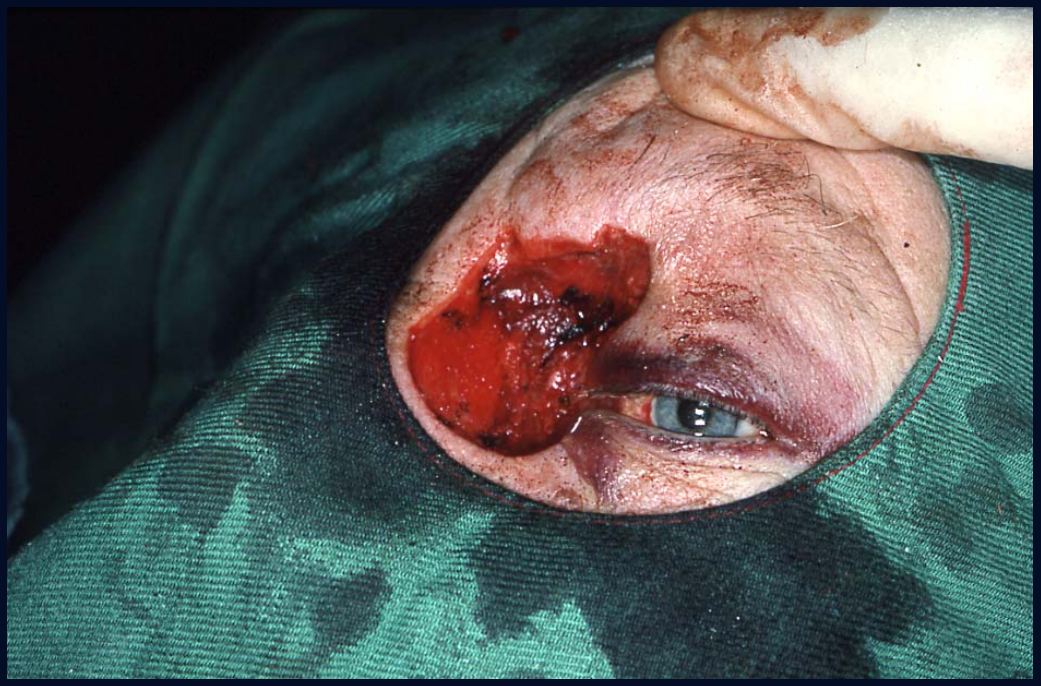

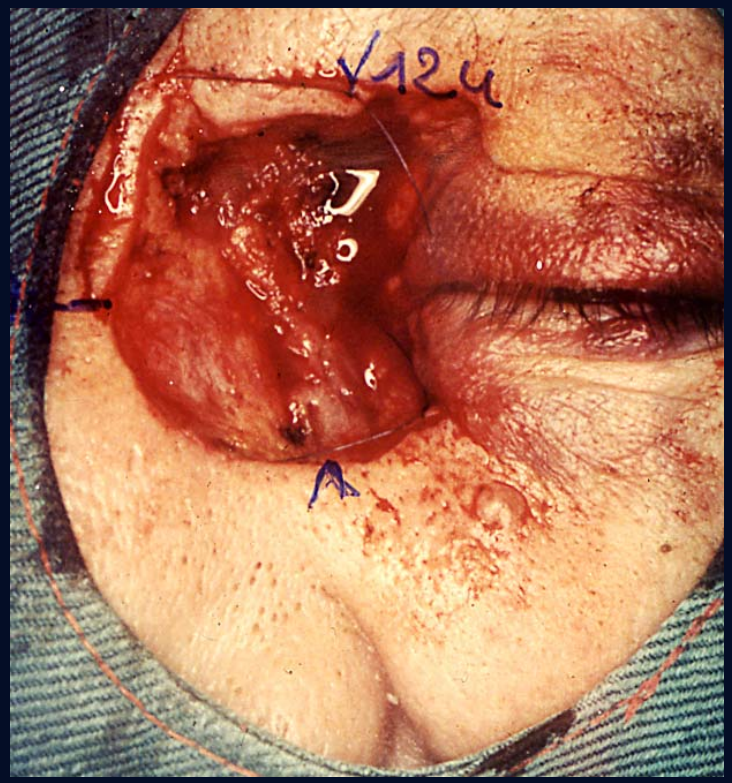
Y124

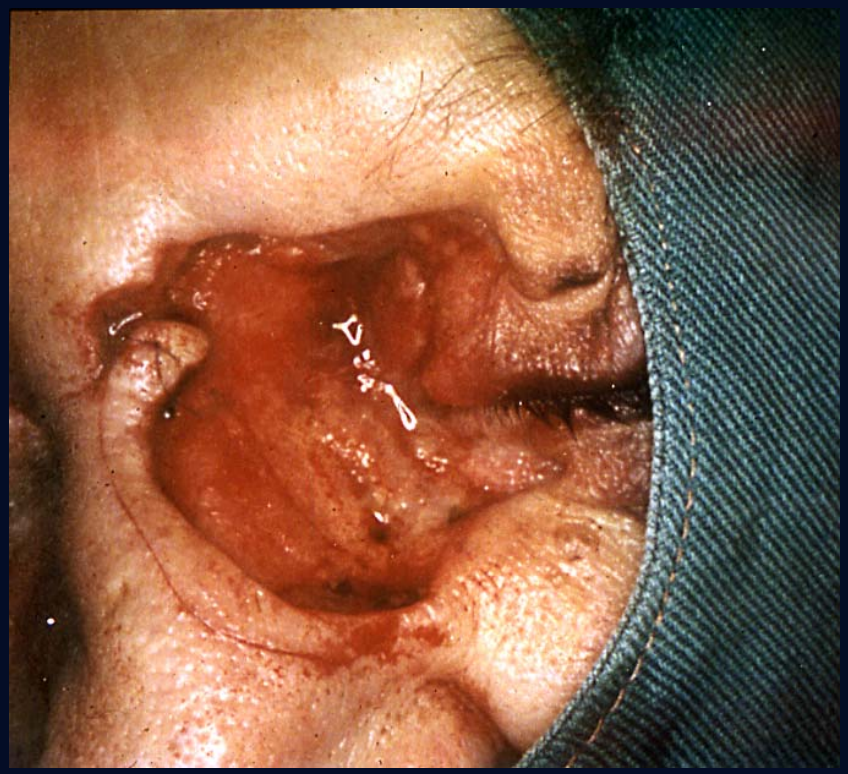

PARAKLINISCHE ONDERZOEKEN

BCC

GROTE, VERWAARLOOSDE, INVASIEVE TUMOREN

- ECHO KLIERLOGES
- CT AANGETASTE REGIO
- OP KLINISCH- ANAMNESTISCHE INDICATIE

FOLLOW – UP BCC

RECURRENCE

MULTIPLE

FOLLOW-UP BCC

- EERSTE JAAR 6 MAANDELIJKS
- NADIEN JAARLIJKS:
  - PRIMAIRE TUMOR: 5 JAAR
  - RECIDIEF: 10 JAAR

MULTIDISCIPLINARY

INVASING VITALE STRUCTURES

RECONSTRUCTION

FUTURE

- PHOTODYNAMIC THERAPY (PDT)
- IMMUNOMODULATORS

ALDARA™ (imiquimod)

- Imidazoquinolone
- Synthetic, local stimulatory IRM
- Potent antiviral and antitumour activity

  proposed antiviral and antitumour effects via induction of cytokines stimulating both the innate and cell-mediated immune responses
- Effects on immune memory

Imiquimod Stimulates both Innate and Acquired Immune Responses

- Imiquimod binds to immune cells predominantly via TLR-7
- Triggers release of cytokines
- Cytokines stimulate innate and cell-mediated responses

Innate immunity

Rapid, non-specific response associated with regression

Adaptive, cell-mediated immunity

Slow, specific response associated with remission

Topical Photodynamic Therapy in Dermato-Oncology

Dr. ARLETTE DE CONINCK UZ Brussel

3 April 2008

Photodynamic therapy requires the presence of 3 components to form Reactive Oxygen Species

GOAL : selective destruction of targeted abnormal cells

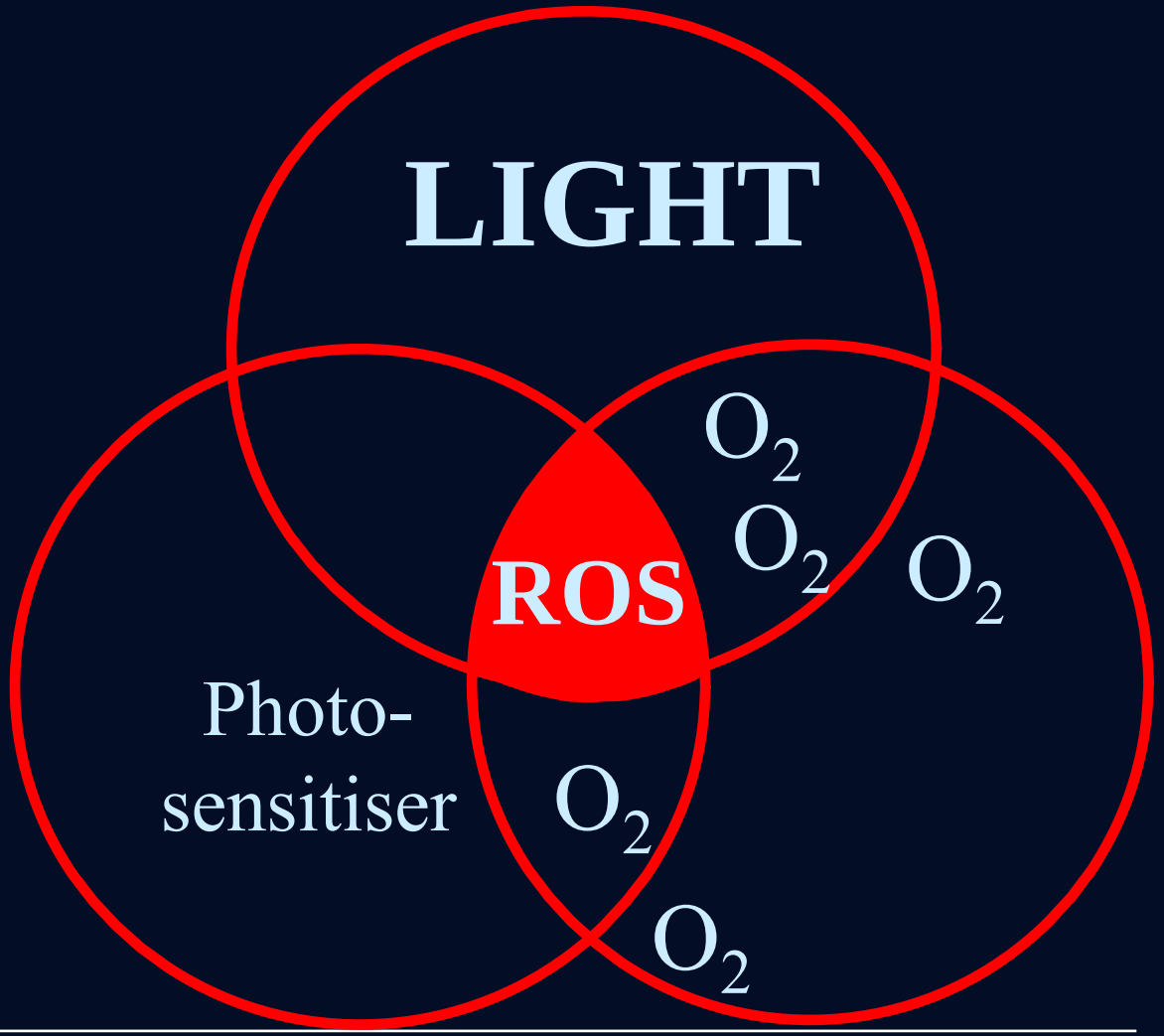

Electromagnetic spectrum

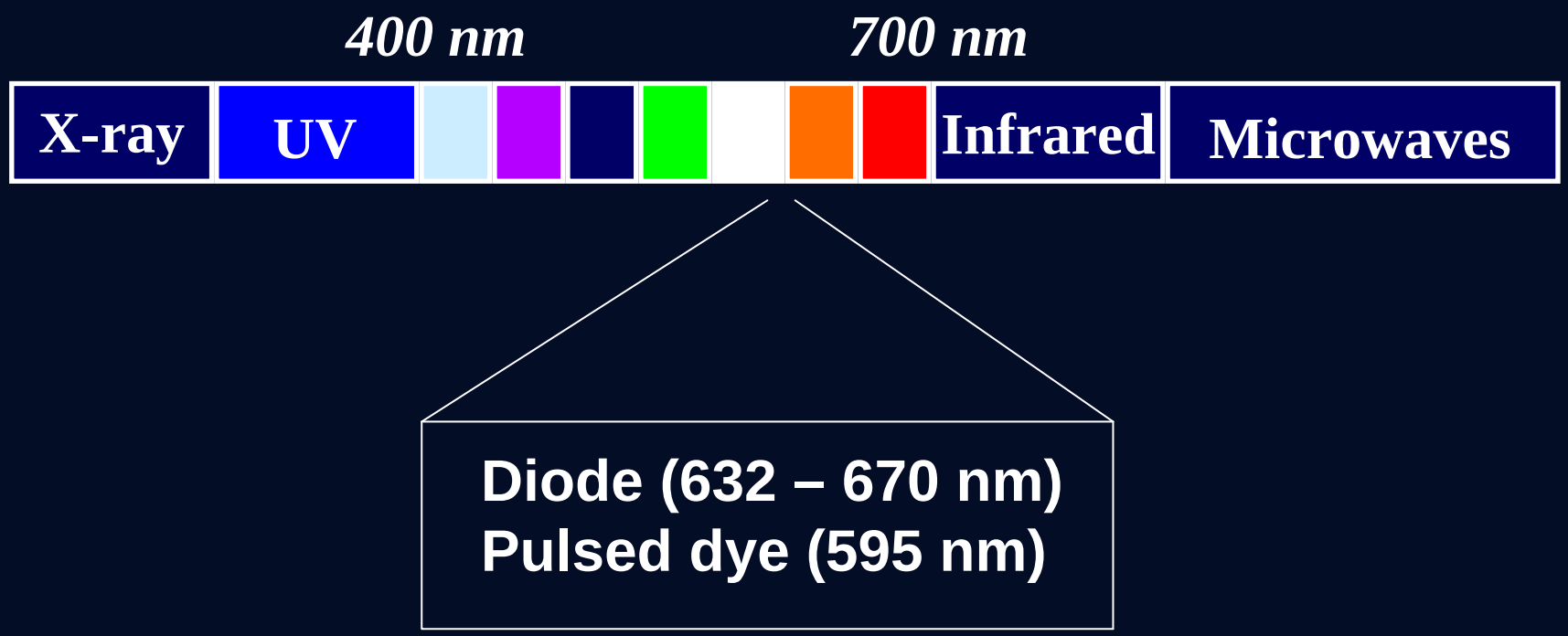

Wavelength and skin penetration

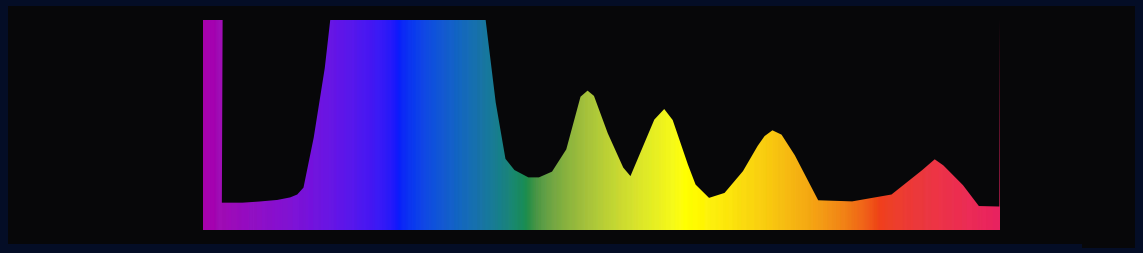

Porphyrin absorption spectrum

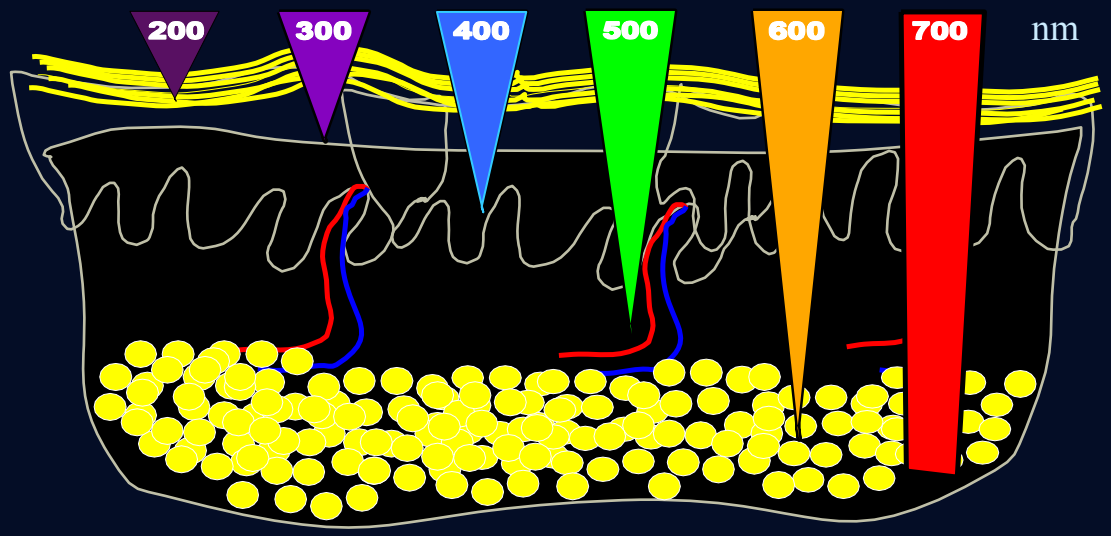

Stratum corneum

Epidermis

Dermis

Subcutis

Indications + contraindications

Indications

- Thin/non-hyperkeratotic and non-pigmented AKs on face and scalp
- sBCC
- nBCC (< 2cm)
- Morbus Bowen

Contraindications

- Morpheaform BCC
- Pigmented BCC
- Hypersensitivity to MAL or any of the excipients
- Porphyria

Treatment procedure

Lesion preparation

- Curette to remove loose scales and crust
- Avoid distressing surrounding skin

Treatment procedure

MAL application

- Apply Metvix about 1 mm thick
- Including 5 – 10 mm normal surrounding skin
- Cover with occlusive dressing
- Leave for 3 hours

Treatment procedure

Illumination

- **Wash off Metvix cream with saline**
- **Illuminate with red light (630 nm)**

AK: Clinical result

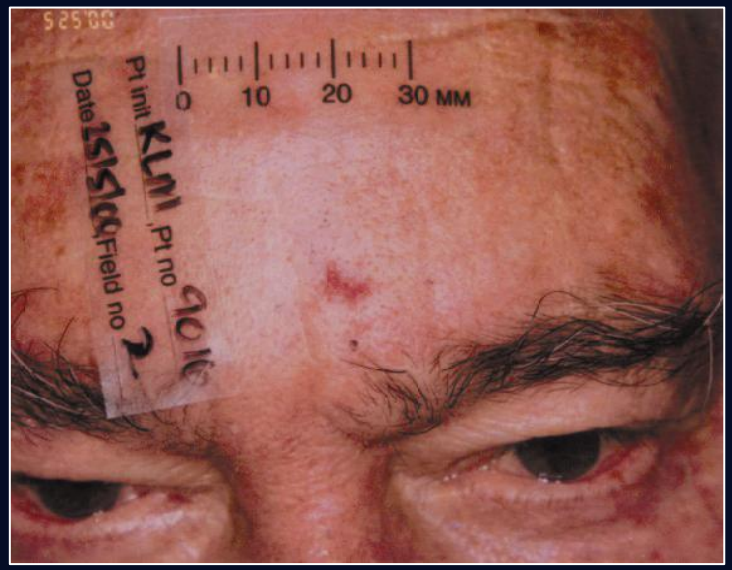

Actinic keratosis before treatment*

Actinic keratosis after Metvix-PDT (two treatment cycles) treatment*, after 3 months

* Pariser DM et al; J Am Acad Dermatol 2003; 48(2): 227-232

BCC: Clinical Result

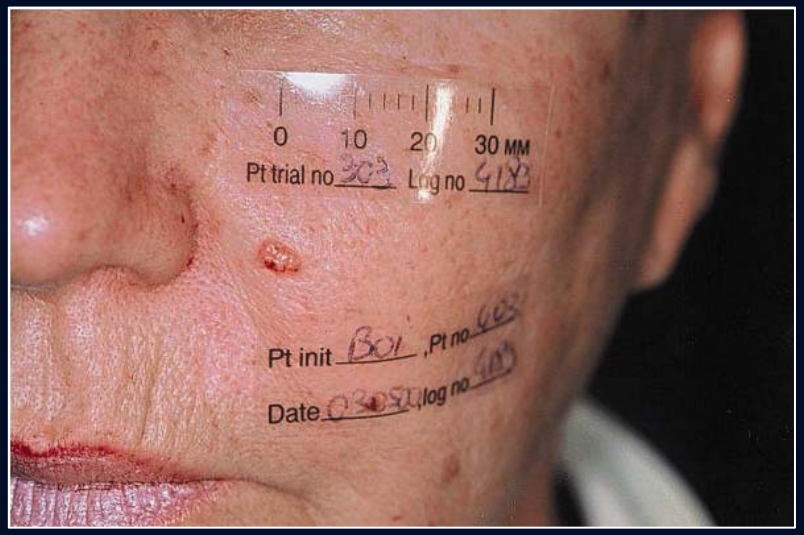

Primary nodular BCC, before treatment*

Complete response after Metvix-PDT (two treatment cycles) treatment, after 3 months

* Rhodes L.E. et al, Poster EADV Barcelone 2003, submitted for publication

BCC



BCC IS A SLEEPING LION

BE AWARE OF IT ! ! ! !

Your first shot is your best shot

Don’t mis your first shot

Squamous Cell Carcinoma

PLAVEISELCELCARCINOOM

de novo **premaligne lesies**

PLAVEISELCELCARCINOOM

ULCERATED BCC

SQUAMOUS CELL CARCINOMA

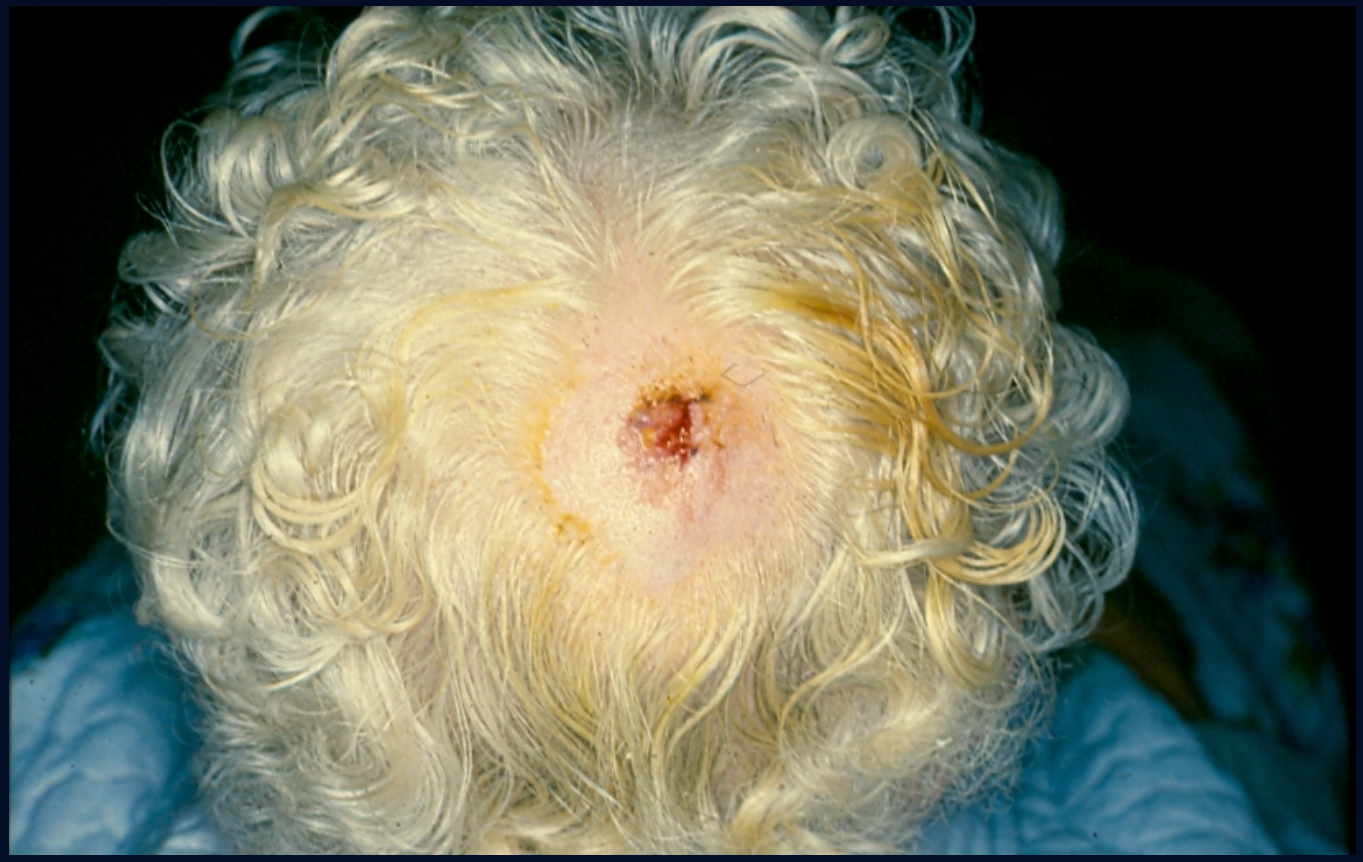

SCC ON A BURN

SCC ON RADIODERMATITIS

SCC ON RADIODERMATITIS

PLAVEISELCELCARCINOOM

SQUAMOUS CELL CARCINOMA

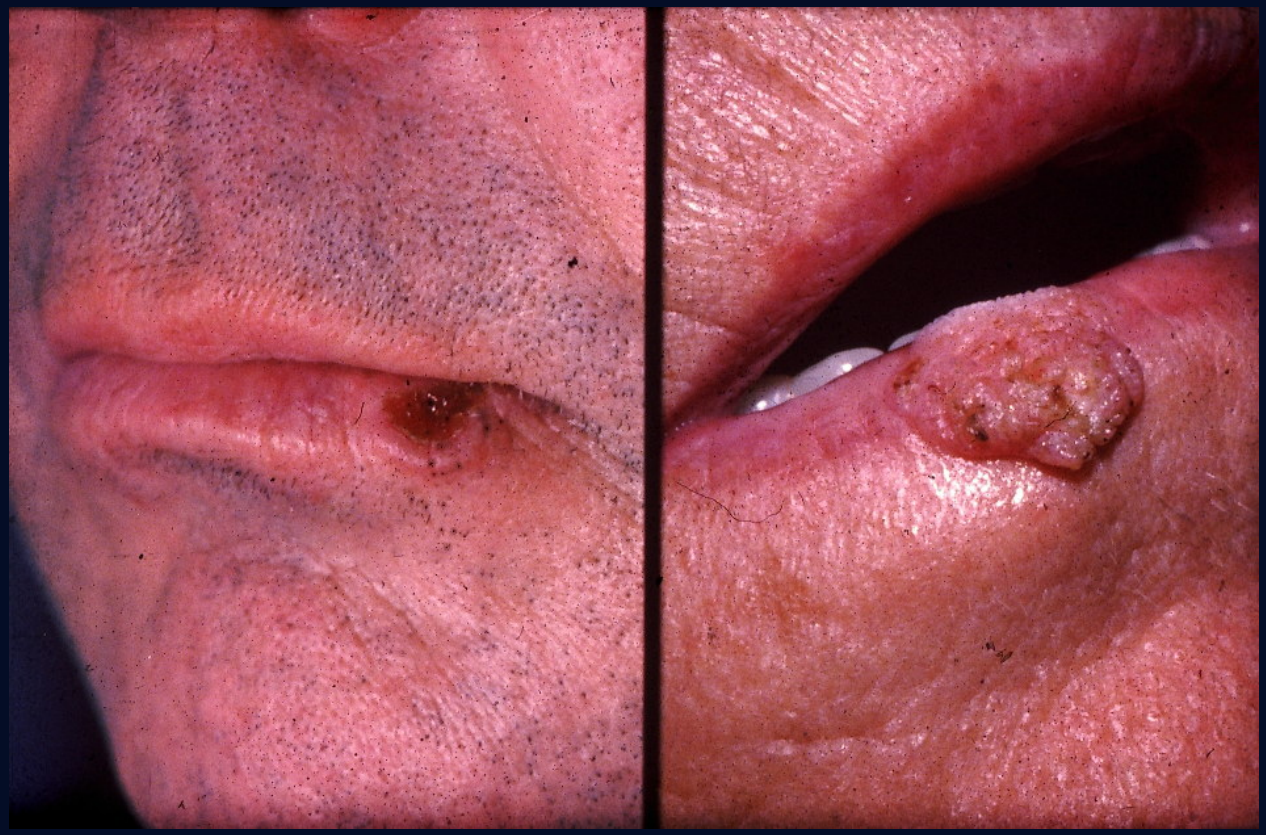

MORBUS BOWEN

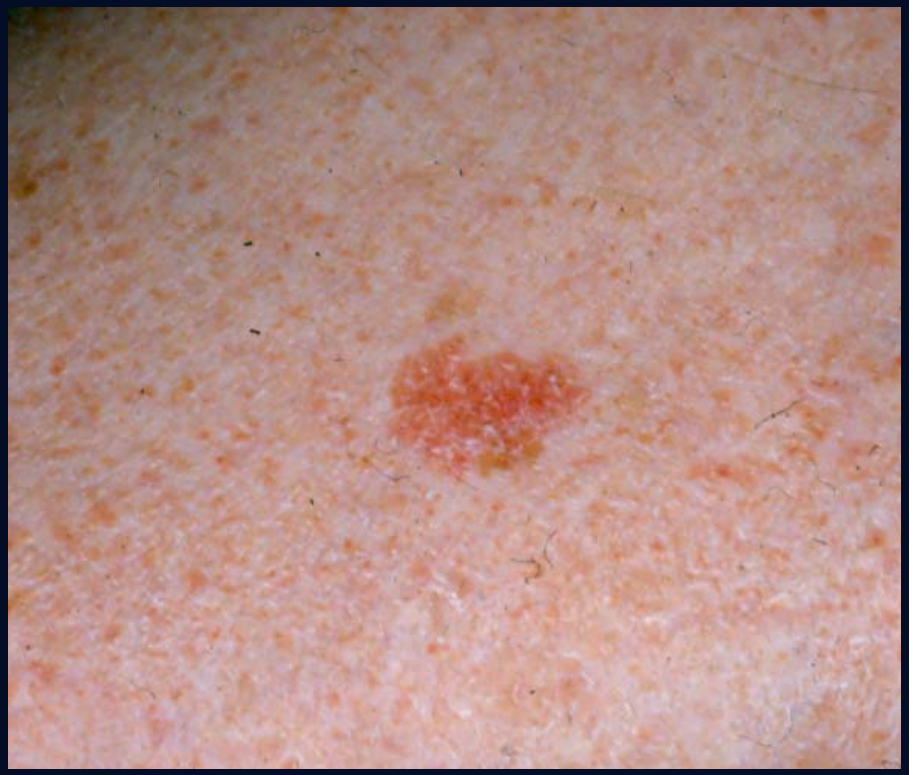

RECURRENT BCC AFTER RADIOTHERAPY

RECURRENT BCC AFTER RADIOTHERAPY

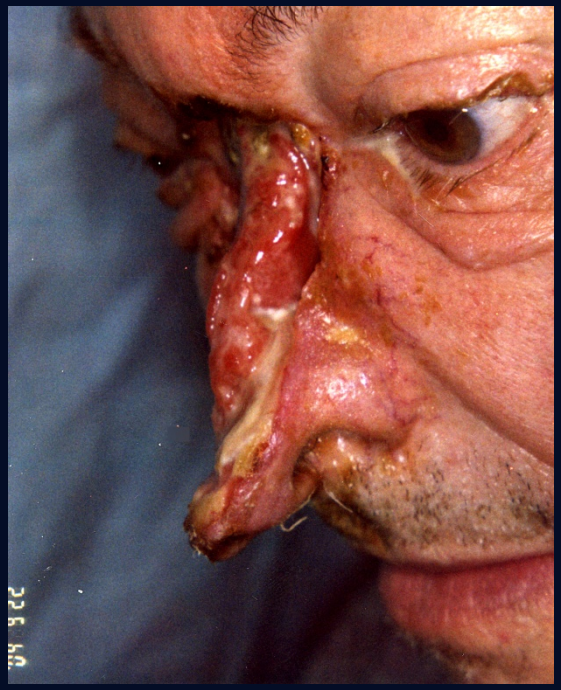

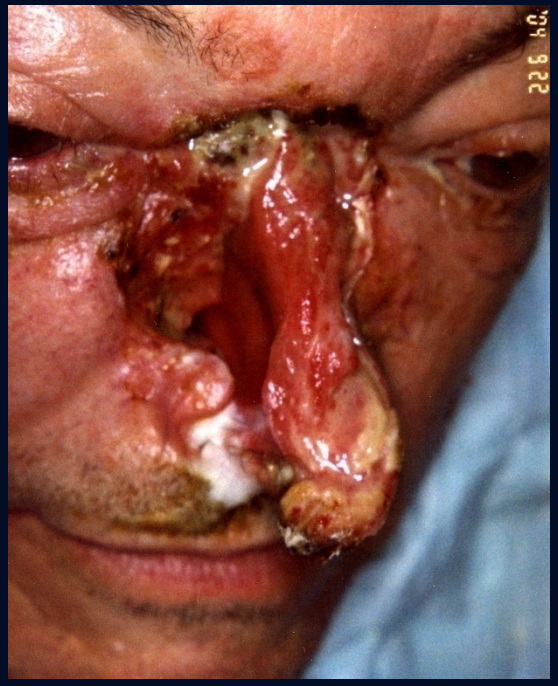

PLAVEISELCELCARCINOOM

LAAG-RISICO

- Kleine, goed begrensde letsels,
- Histopathologische "in situ" letsels
  - carcinoma in situ
  - Morbus Bowen

HOOG-RISICO

- Langbestaande tumor, of
- Snelgroeiende tumor, of
- Tumor > 2 cm diameter, of
- Immunosupressie, of
- Localisatie: H-zone, anogentiale regio, voetzool, de zgn. littekencarcinomen (brandwonden, chronische ulcera, postradio- therapie….), of
- Histopathologische kenmerken:

  invasieve groei > 4 mm en of dieper dan subcutaan weefsel,

  differentiatiegraad: goed-matig-slecht,

  histopathologische varianten: adenoid SCC, verruceus carcinoom,,

  perineurale/lymfatische/vasculaire invasie, of
- Recidiverende SCC, of
- SCC van de slijmvliezen (erythroplasie van Querat)

PARAKLINISCHE ONDERZOEKEN

SCC

LAAG- EN HOOG RISICO

LABO
RX THORAX
ECHO KLIERLOGES

VERDACHTE KLIER

DUNNE - NAALD – PUNCTIE
BIOPSIE

POSITIEVE KLIER

- PET SCAN
- NMR HERSENEN
- BIJKOMENDE ONDERZOEKEN VOLGENS KLINISCHE- ANAMNESTISCHE GEGEVENS

STAGING SCC

- T-CLASSIFICATIE (PRIMAIRE TUMOR)
- N- CLASSIFICATIE (REGIONALE LYMFEKLIEREN
- M-CLASSIFICATIE (METASTASEN OP AFSTAND)
- G-CLASSIFICATIE (HISTOPATHOLOGISCHE GRADERING)

HISTOPATHOLOGIE

- GROEIPATROON EN CELMORFOLOGIE
- DIFFERENTIATIEGRAAD : GOED – MATIG – SLECHT
- INVASIEVE DERMALE GROEI IN MM
- AANWEZIGHEID REGRESSIE, ULCERATIE, INFLAMMATIE
- PERINEURALE / VASCULAIRE / LYMFATISCHE
- TUMORVRIJE SNIJRANDEN

BEHANDELING SCC

LAAG RISICO

AFHANKELIJK VAN DE EXPERTISE VAN DE BEHANDELENDE ARTS

- HEELKUNDIGE EXCISIE
- CURETTAGE + ELECTRODESICCATIE
- CRYOCHIRURGIE
- PHOTODYNAMISCHE THERAPIE
- IMMUNOMODULATOREN

HOOG RISICO

- MICROGRAFISCHE HEELKUNDE
- RADIOTHERAPIE (CONTRA-INDICATIE HEELKUNDE)

FOLLOW – UP SCC

KLINISCH

LAAG RISICO

- EERSTE JAAR
  6 MAANDELIJKS
- NADIEN JAARLIJKS

HOOG RISICO

- EERSTE JAAR
  3 MAANDELIJKS
- VANAF 2DE JAAR
  6 MAANDELIJKS
- NADIEN JAARLIJKS

FOLLOW – UP SCC

PARAKLINISCHE ONDERZOEKEN

- JAARLIJKS LABO, RX THORAX, ECHO KLIERLOGES OF OP KLINISCH-ANAMNESTISCHE INDICATIE

- GEMETASTASEERDE TUMOREN BIJKOMENDE GERICHTE ONDERZOEKEN

MELANOMA

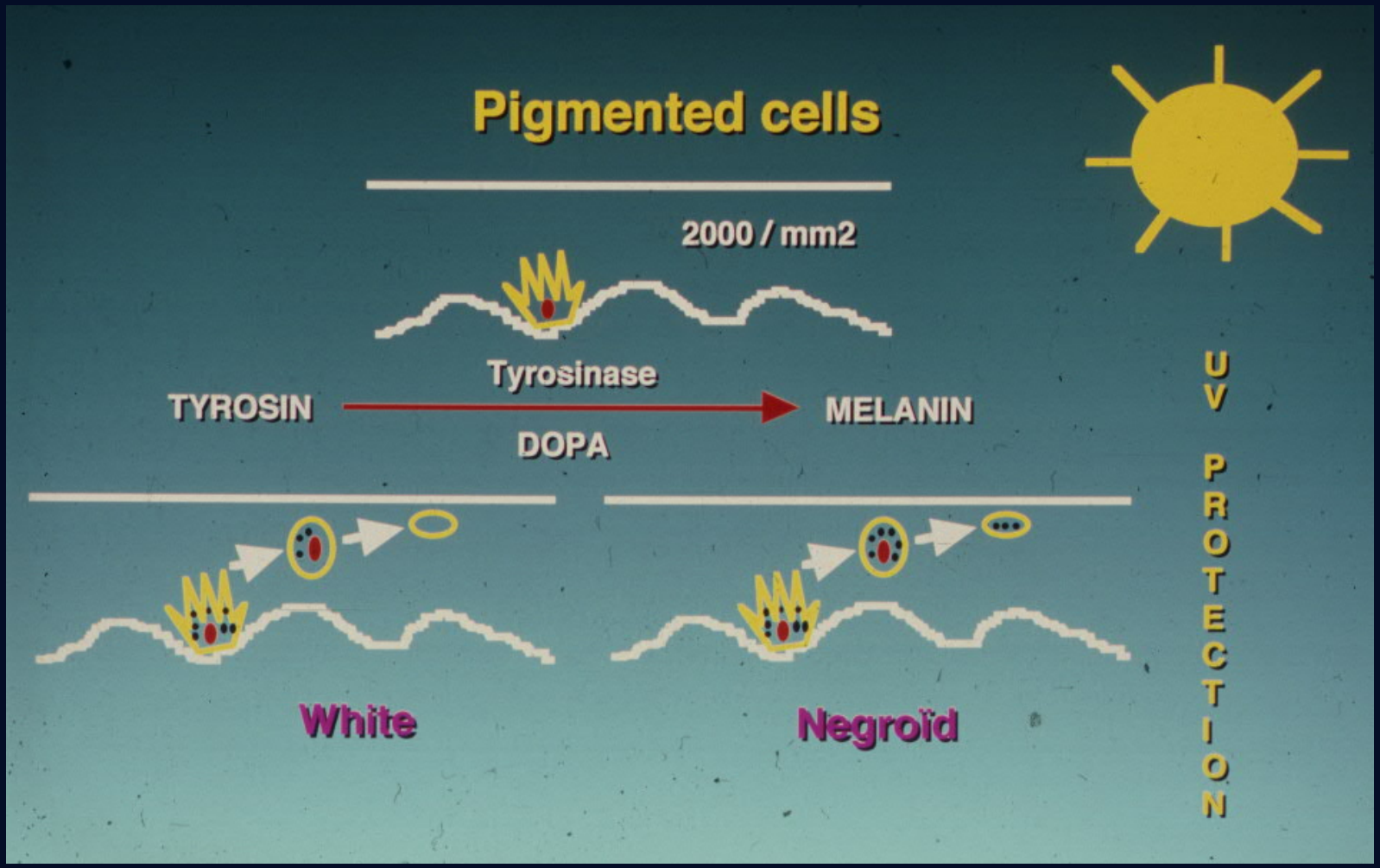
Pigmented cells
2000 / mm2
Tyrosinase
TYROSIN
MELANIN
DOPA
White
Negroïd
UV PROTECTION

TAN

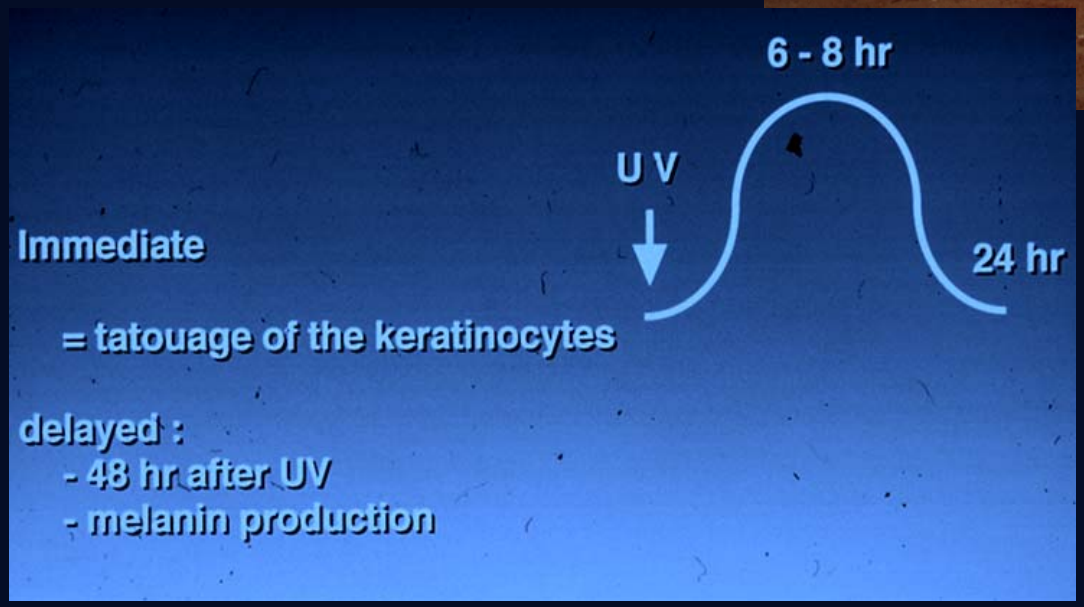
6 - 8 hr
U V
24 hr
Immediate
= tatouage of the keratinocytes
delayed :
- 48 hr after UV
- melanin production

PHOTOTYPES

Epidemiology

(Back) ♂ ≃ ♀ (Legs)

↗ Incidence - USA: 1%
- Australia 1 in 60

(White population – Celtics)

↗ Death rate: doubled in 20 years

A: asymmetry

B: border

C: colour

D: diameter

E: evolution

Remember the ABCDs

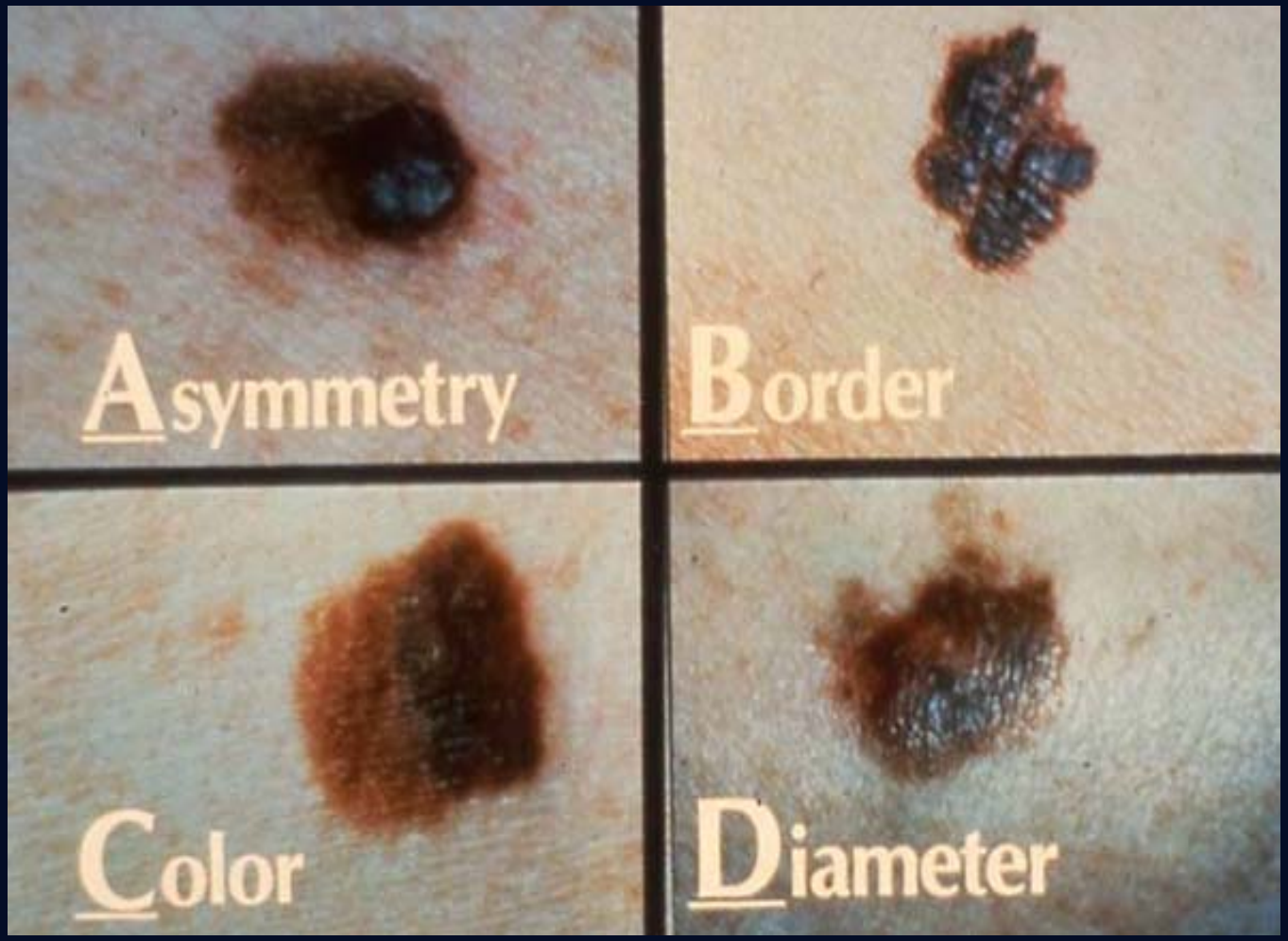

Malignant Melanoma

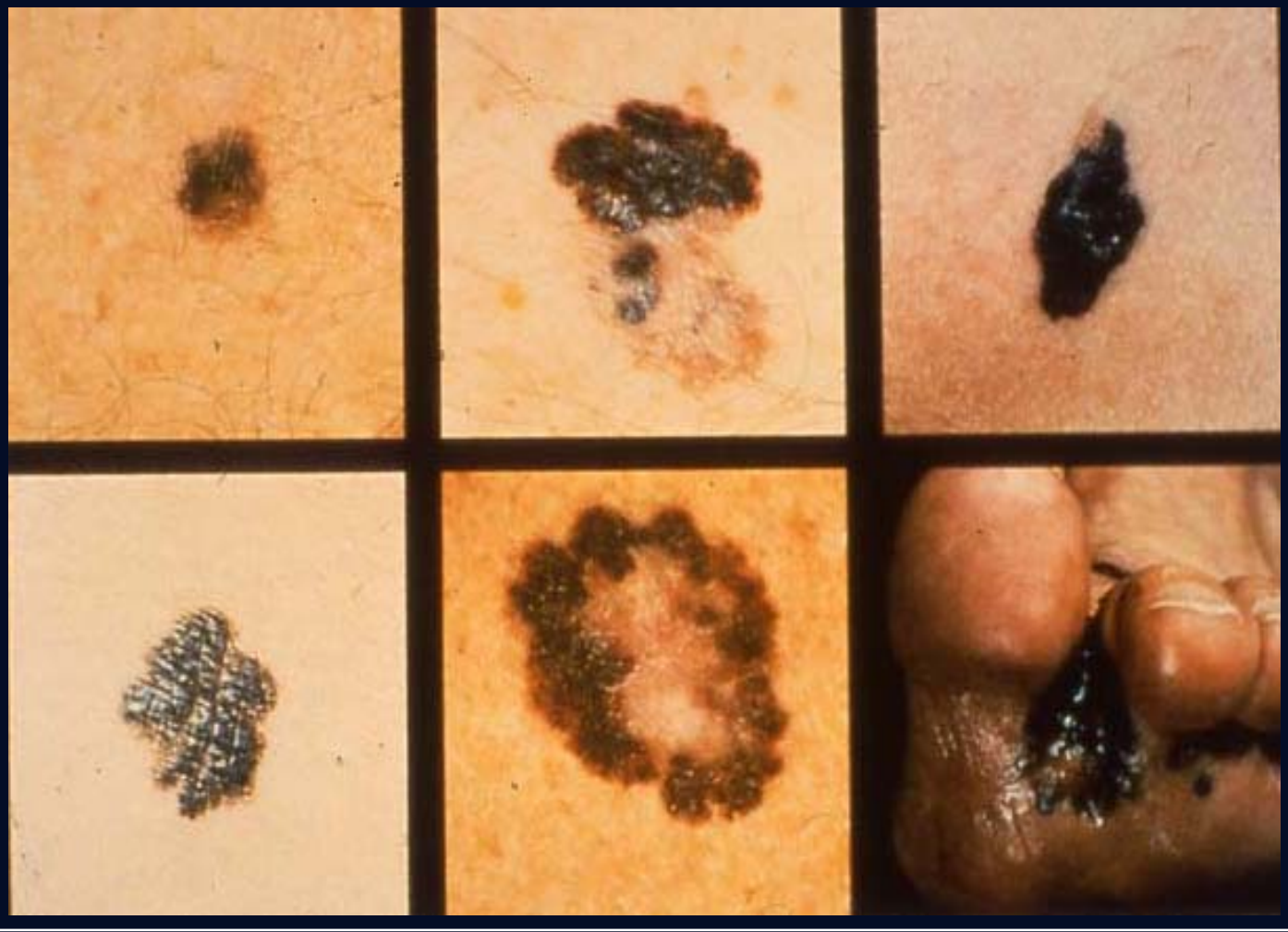

MELANOMA

- SUPERFICIAL SPREADING MELANOMA
- NODULAR MELANOMA
- LENTIGO MALIGNA MELANOMA
- ACRAL LENTIGINOUS MELANOMA

SSM

SSM

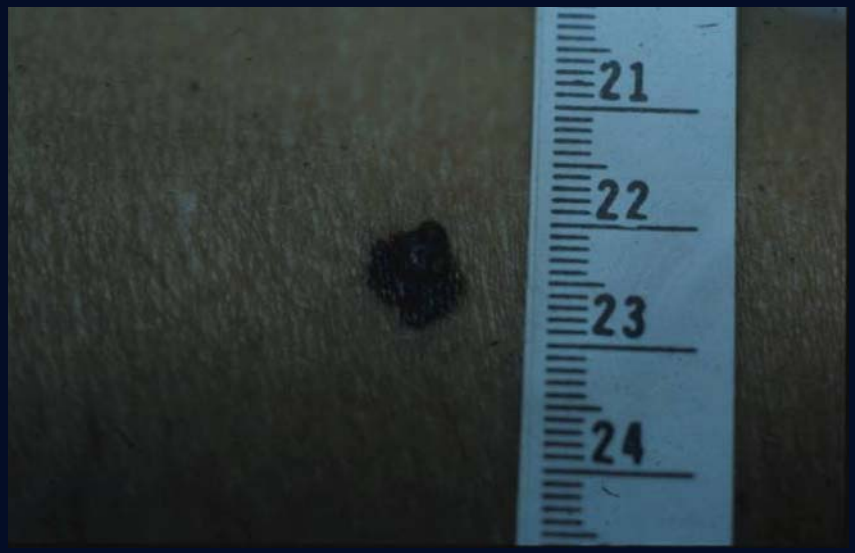

SUPERFICIAL SPREADING MELANOMA

SUPERFICIAL SPREADING MELANOMA WITH NODULAR COMPONENT

SUPERFICIAL SPREADING MELANOMA

NODULAR MELANOMA

NODULAR MELANOMA

CAVE AMELANOTIC MELANOMA !

AMELANOTIC MELANOMA

LENTIGA MALIGNA MELANOMA

LMM

“older” people, sun exposed skin

ALM

- palmoplantar,mucosa
- amelanotic !

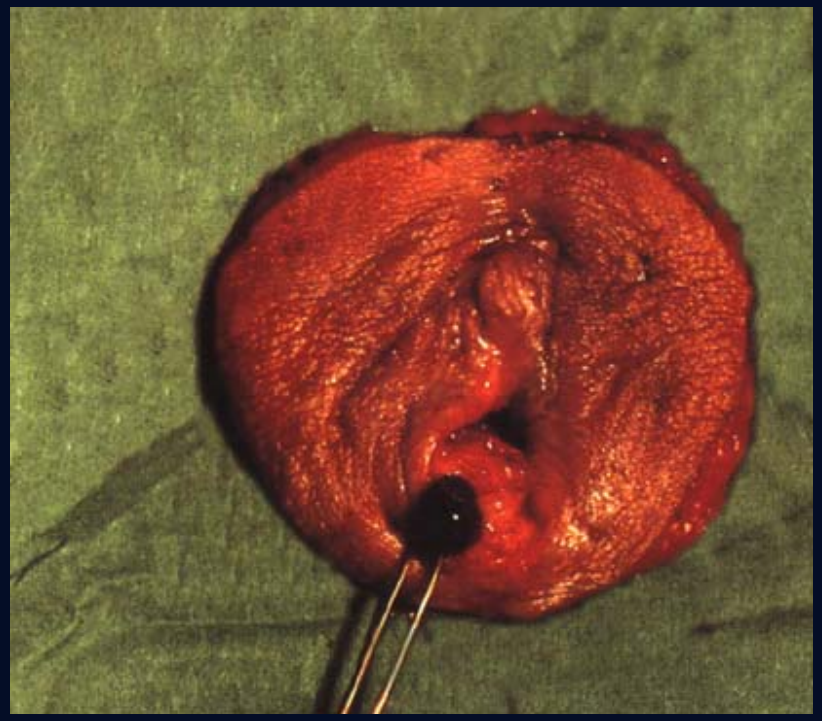

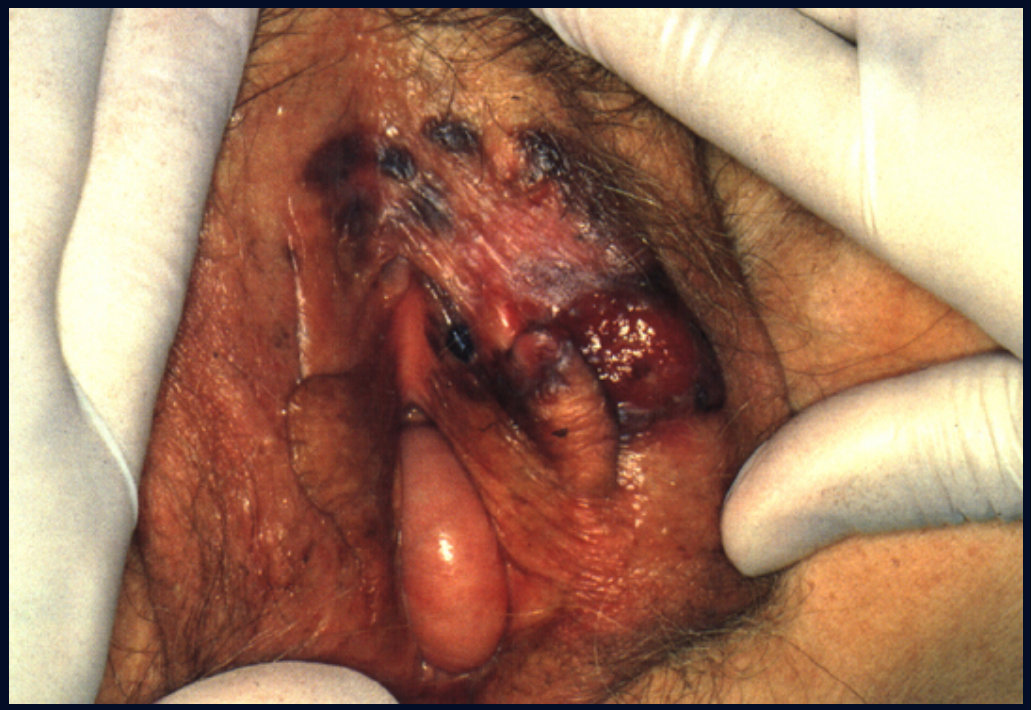

PROGNOSTIC CRITERIA

- Histologic type
- Clark (I→V)
- Ulceration
- Mitosis

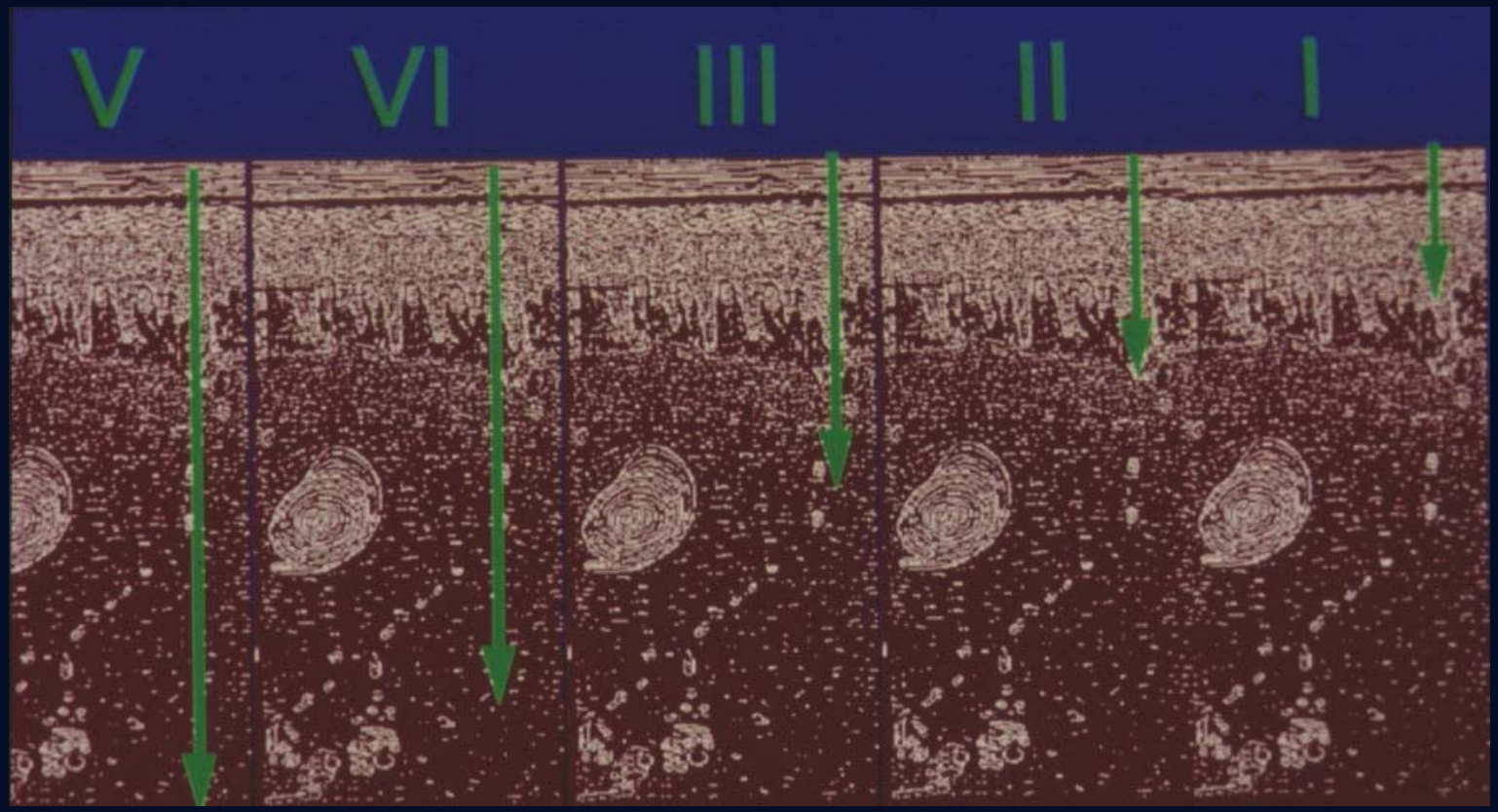
V
VI
III
II
I

Indeling in stadia volgens de nieuwe AJCC criteria

AJCC	TNM STAGE	CRITERIA FOR STAGING
IA	T1aNoMo	T1a = Breslow ≤ 1mm, no ulceration (U-) and Clark level < III
IB	T1bNoMo	T1b = Breslow ≤ 1mm, with ulceration (U+) or Clark level ≥ IV
	T2NoMo	T2b = Breslow 1.01 – 2.0 mm U-
IIA	T2b/T3NoMo	T2b = Breslow 1.01 – 2.0 mm, U+/T3 = 2.0 – 4.0 mm U-
IIB	T3b/T4aNoMo	T3b = Breslow 2.01 – 4.0 mm U+/T4> 4.0 mm U-
IIC	T4bNoMo	T4b = Breslow > 4mm U+
IIIA	Any TaN1a/N2aMo	U-, N1a = 1 lymph node microscopically + / N2 = 2 –3 nodes
IIIB	Any TbN1a/N2aMo	U+, N1a = 1 lymph node microscopically + / N2 = 2 –3 nodes
IIIC	Any TbN1b/N2bMo	U+, N1b = 1 lymph node macroscopically + / N2 = 2 –3 nodes
	Any TN3Mo	U- or U+, N3 ≥ 4nodes, satellite or in-transit metastases
IV	Any T any NM1a	M1a = nodal metastases with normal LDH distant skin, subcutaneous with normal LDH
	Any T any NM1b	M1b = lung metastases with normal LDH
	Any T any NM1c	M1c = LDH elevated and/or any non-pulmonary visceral metastases

MARGINS OF SURGICAL EXCISION

$\leq$ 1 mm : 1 cm

$\geq$ 1 mm : 2 - 3 cm

MELANOOM

- Stadium I
- Stadium II
- Stadium III
- Stadium IV

MELANOOM Stadium I en II

- **Diagnostiek:**
- Excisie: - 2 mm lateraal
  - Diep tot subcutis
  - Ellips in richting regionale lymfeklierloge
- **Incisie:** welbepaalde letsels (groot, moeilijke localisatie)
- **Therapie** : - snijranden: Breslow < 1 mm: 1cm
  > 1 mm: 2 cm tot op fascia
  - sentinelklierbiopsie
  - adjuvante behandeling

MELANOOM Stadium I en II

❑ Staging:

- Klinisch
- Histopathologisch
- Paraklinische onderzoeken:

  -alle melanomen: routine bloedonderzoek, Rx Thorax, echo klierloges

  - invasieve melanomen: (add): Echo abdomen, PET-scan, NMR hersenen

❑ Follow-up: Klinisch – zelfonderzoek !

- Klinisch: - eerste 2 jaar 3 maandelijks

  - nadien om de 6 maanden (10 j. of levenslang)
- Paraklinisch: 1x per jaar of op klinisch-anamnestische indicatie

HISTOPATHOLOGISCHE CRITERIA

- BRESLOW DIKTE
- ULCERATIE
- CLARK NIVEAU
- REGRESSIE
- HISTOLOGISCH SUBTYPE

MELANOOM Stadium III en IV

?

MELANOMA

loco-regional recurrence

MELANOMA

loco-regional recurrence

Risicofactoren melanoom

- Notie zonnebrand (fototypes I – II)
- Groot aantal naevi (dysplastische)
- Frequente zonneblootstelling tijdens kinderjaren
- Grote congenitale naevi

Zonnebrand

Sproeten = zonnebrand als kind

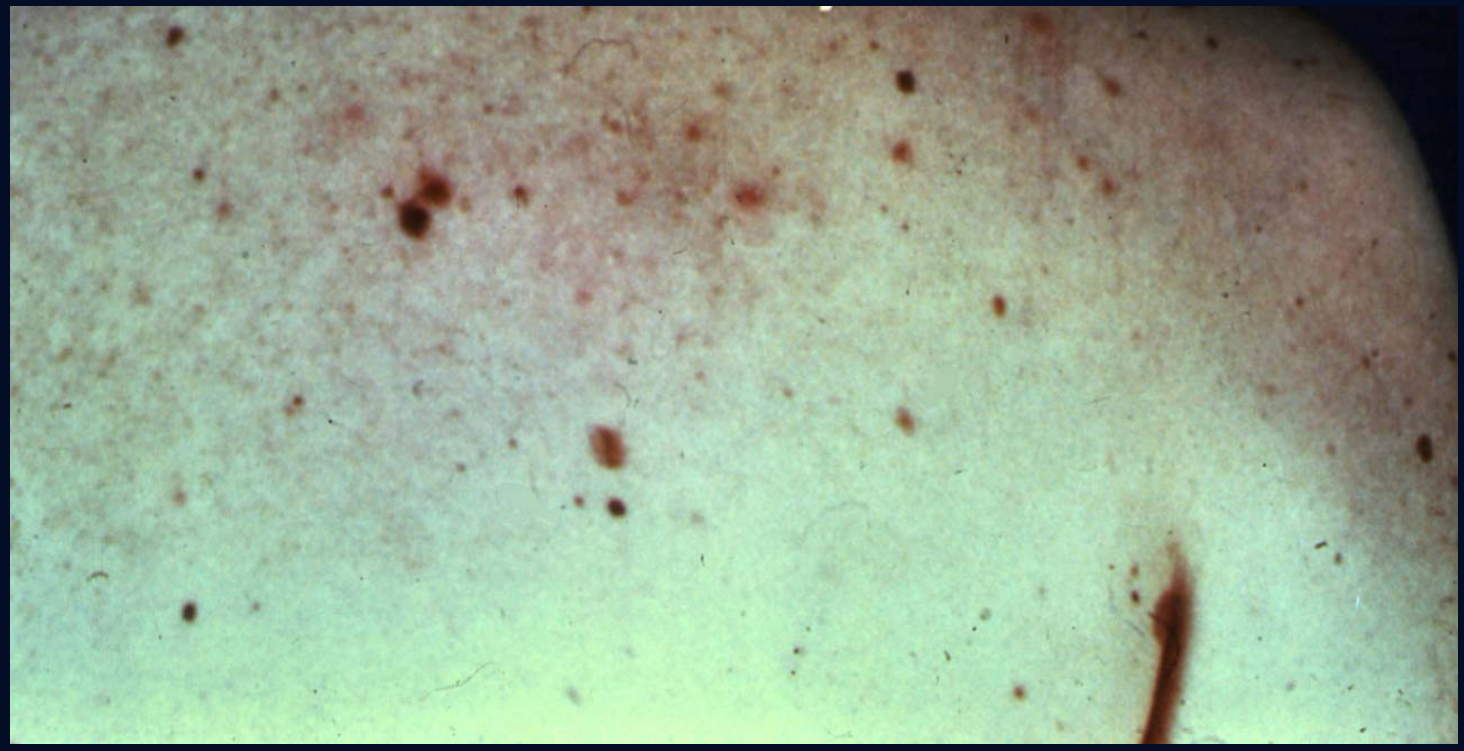

Verhoogd risico voor melanoom en basaalcelcarcinoom

DYSPLASTIC NAEVI

CONGENITAL NAEVUS

Skin Cancer: Preventable and curable

EARLY DIAGNOSIS

AND

PROMPT REMOVAL

CURE

Know The Signs Of Skin Cancer

Warning Sign:
CHANGE

REMEMBER The ABCDs

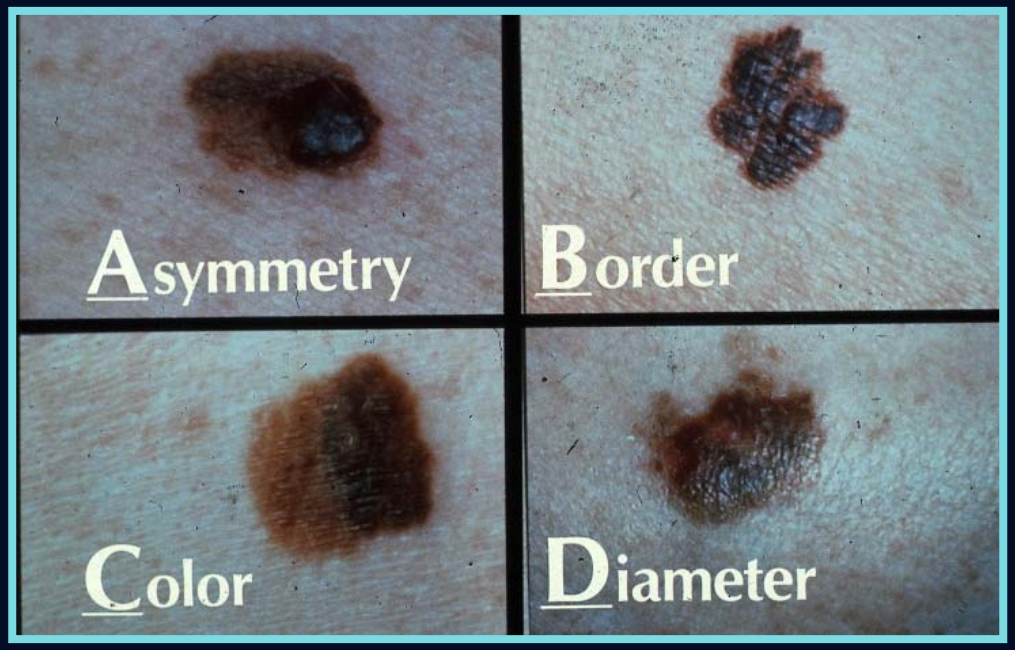



http://www.pless.fr/dermatoscopie

NAKED EYE

ELM

epiluminescence microscopy

Stolz Algorithm

- Benign junctional nevus

Asymmetry: 0 x 1.3	Borders: + 0 x 0.1
Colors: + 1 x 0.5	Different signs: + 2 x 0.5

Score = 1,5

Close

Naked eye appearance: brown fairly poorly defined lesion somewhat paler peripherally

ELM findings: fine and regular network cutting gradually at periphery. Rare darker black dots at centre of lesion

NAKED EYE

ELM FINDINGS

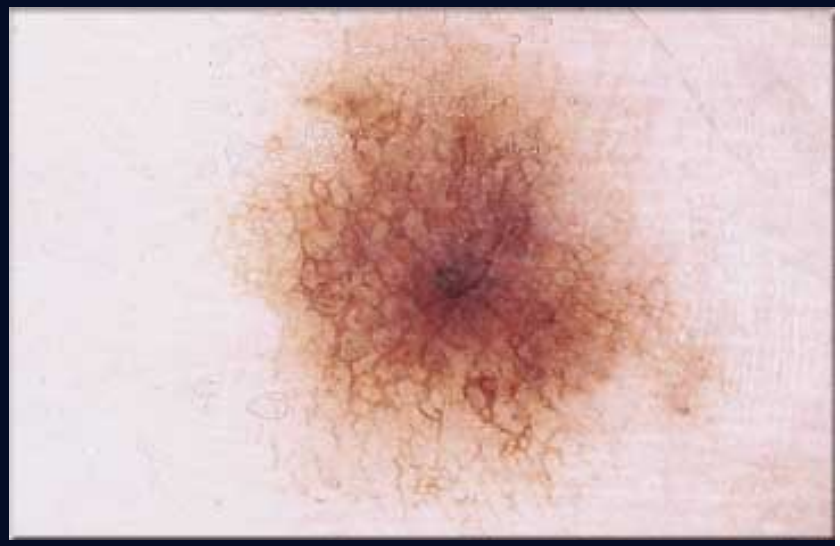

Naked eye appearance : well-defined black tumor slightly brown at periphery, this lesion known since childhood but has increased a little in size in recent months.

ELM findings : network scarcely visible at periphery, with rare extensions including one forming a pseudo pod, most of the lesion being occupied by structure less area, black to grey in color, with milky veil at center of lesion.

NAKED EYE

ELM FINDINGS

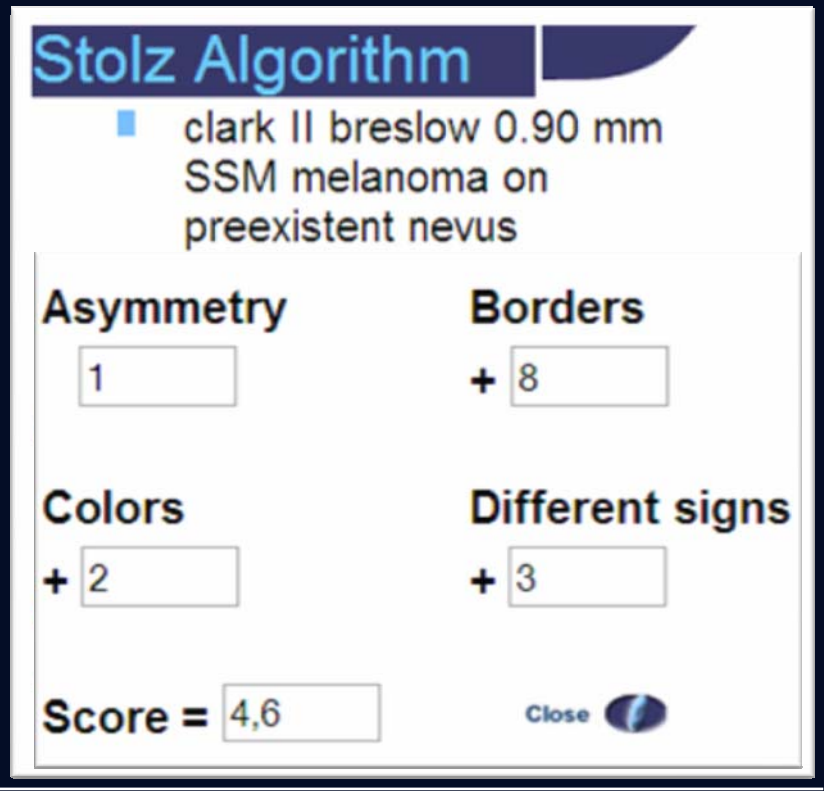

DERMATOSCOPY

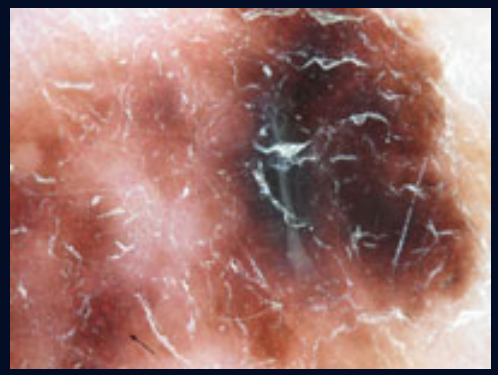

Early melanoma

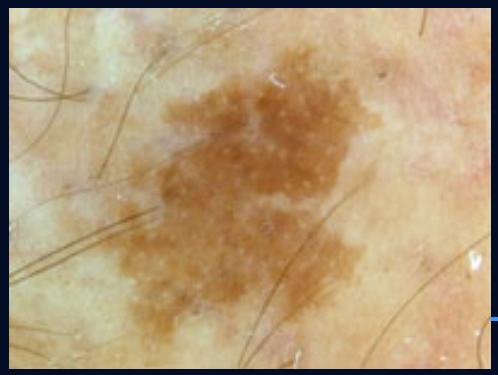

Benign lentigo

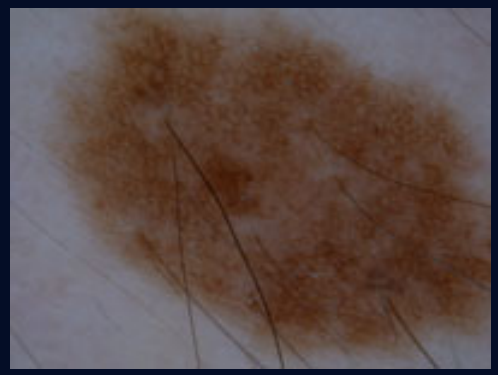

Benign melanocytic naevus

Seborrhoeic keratosis

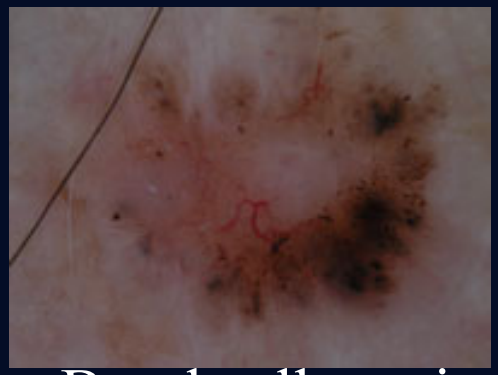

Basal cell carcinoma

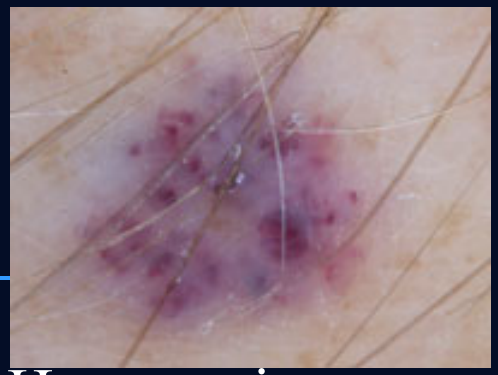

Haemangioma

PREVENTION

Stralingsintensiteit zon

→ **zeespiegel**
→ **gebied**
→ **jaargetijde**

PHOTOTYPE

PHOTOTYPES

Stralingsintensiteit

- seizoen
- uur van de dag
- breedtegraad
- altitude

Belgische zomerdag

- 6 mW/cm^2 UVA
- 0,2 mW/cm^2 UVB

UV-index

Hoeveelheid UV aanwezig rond middaguur

UV-index	UV- intensiteit	Huid verbrandt
1-2	Zeer laag	Vrijwel niet
3-4	Laag	Langzaam
5-6	Matig	Gemakkelijk
7-8	Hoog	Snel
9-10 en meer	Zeer hoog	Zeer snel

IN BELGIE UV-INDEX ZELDEN > 7

Lifetime risico op melanoom

BELGIE	USA , AUSTRALIE
1/450 MANNEN 1/300 VROUWEN	AANTAL VERDUBBELT OM DE 10 JAAR

UV-bescherming

UV-bescherming

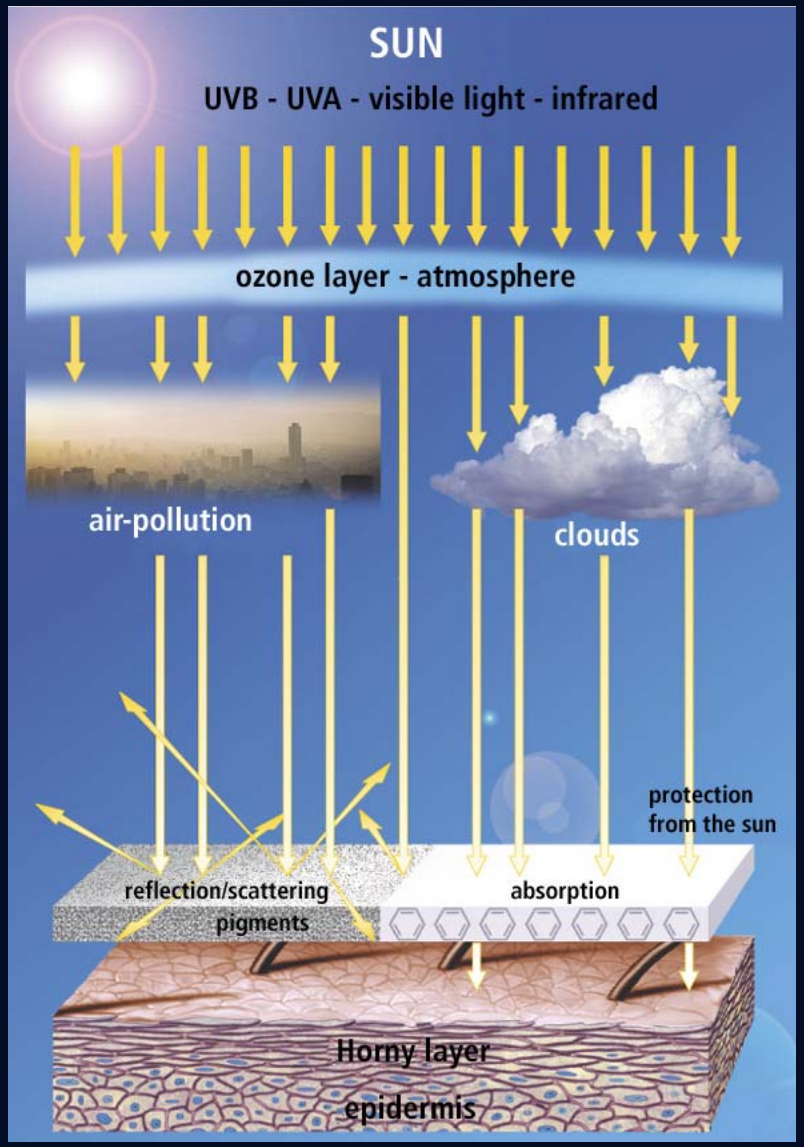
SUN
UVB - UVA - visible light - infrared
ozone layer - atmosphere
air-pollution
clouds
protection
from the sun
reflection/scattering
pigments
absorption
Horny layer
epidermis

- gebruik beschermende zonnecrèmes (waterproof, volgens huidtype, S.I)
- Mijd UV piekuren 11.00-15.00 (siesta)
- Wind, bewolkt: ↓ warmtegevoel
- Weerkaatsing UV op sneeuw, zand, water
- UV's dringen door water en glas
- Cave bepaalde medicaties (NSAI)

MERKEL CELL CARCINOMA

cutaneous neuro-endocrine carcinoma

- related to UV exposition
- M = F ; usually > 50 y
- firm asymptomatic nodule
- high rate of recurrence after excision
- head and neck and extremities
- spreads to lymphnodes in > 50 %
- θ: Micrographic surgery + radio θ

MERKEL CELL CARCINOMA

APUD System (Amine Precursor Uptake and Decarboxylation)

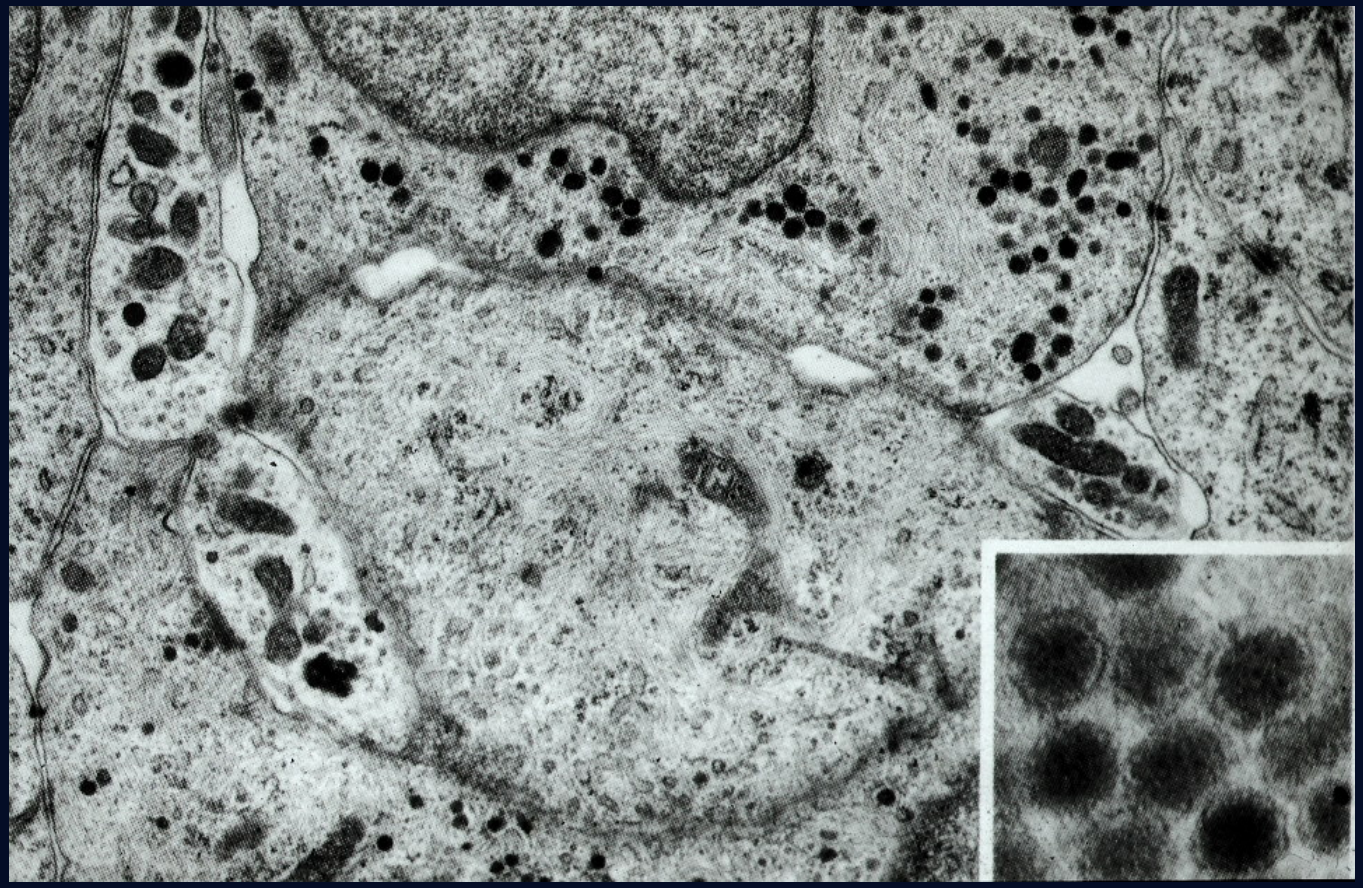

MERKEL CELL CARCINOMA

MERKEL CELL CARCINOMA

MERKEL CELL CARCINOMA

MERKEL CELL CARCINOMA

RECURRENCES MERKEL CELL CARCINOMA

MERKEL CELL CARCINOMA

SARCOMA'S
malignant soft tissue tumors

- Dermatofibrosarcoma
- Leiomyosarcoma
- Angiosarcoma
- Chondrosarcoma

DERMATOFIBROSARCOMA PROTUBERANS (DFSP)

- ESTIMATED INCIDENCE: 0,08/100.000
- HISTOGENESIS UNCLEAR: FIBROBLASTIC?
- CYTOGENETICALLY: CHROMOSOMAL ABNORMALITIES (SUPERNUMERARY RING CHROMOSOME)
- HISTORY OF TRAUMA?

14 YEAR OLD CAUCASIAN GIRL

V.N.

- SINCE 6 MONTHS ERYTHEMATOUS PLAQUE LEFT LUMBAL REGION
- INITIAL DIAGNOSIS: INSECT STING
- PROGRESSIVE EXTENSION AND INDURATION

CUTANEOUS EXAMINATION

V.N.

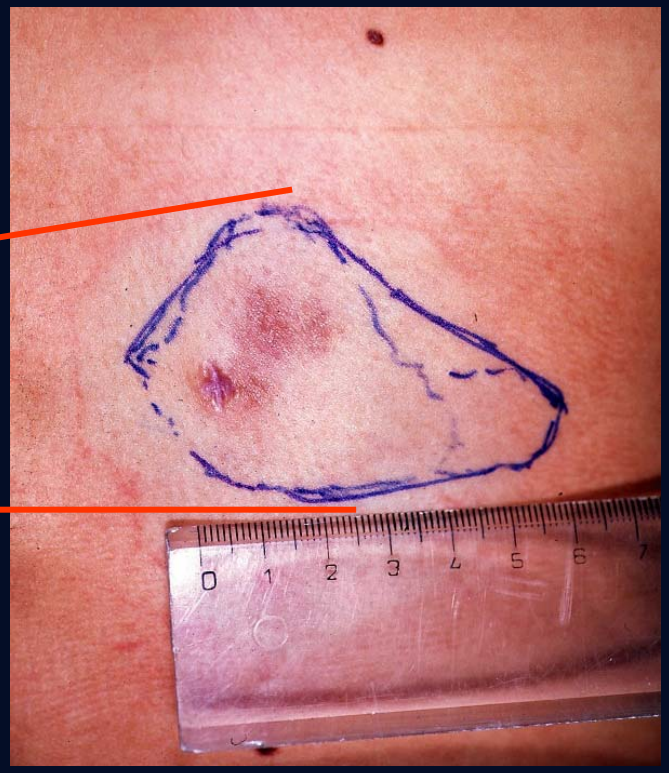

- **RED-BROWN NODULAR LESIONS**
- **INDURATION (SCLERODERMIFORM) BEYOND CLINICAL MARGINS**
- **SIZED 7 BY 4 CENTIMETRE**

EXCISION WITH ONE CENTIMETRE SAFETY MARGIN, ADJACENT TO THE FASCIA.

V.N.

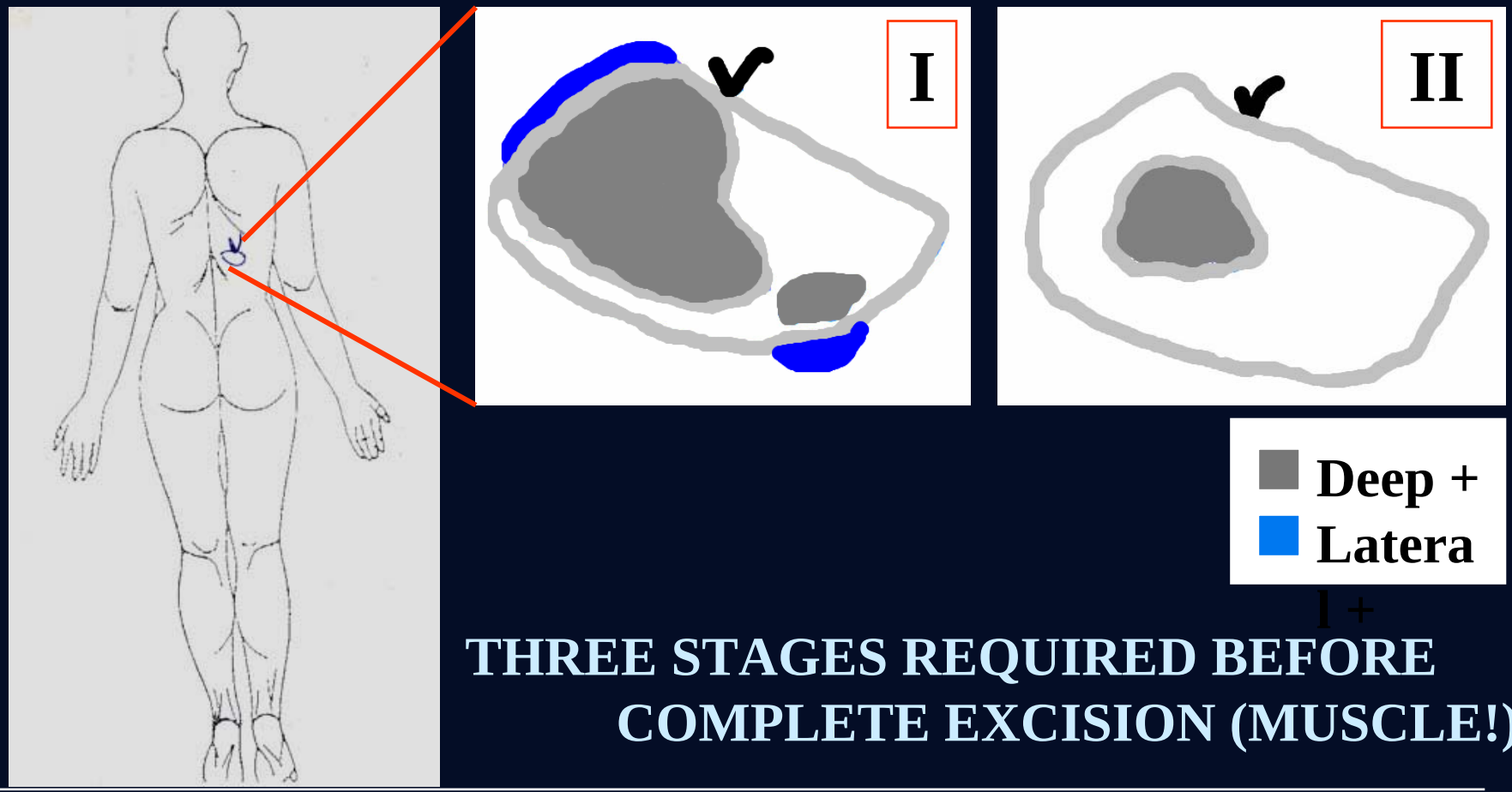

THREE STAGES REQUIRED BEFORE COMPLETE EXCISION (MUSCLE!)

COMPLEX ASYMMETRIC GROWTH CHARACTERISTICS



ASYMMETRICAL GROWTH !

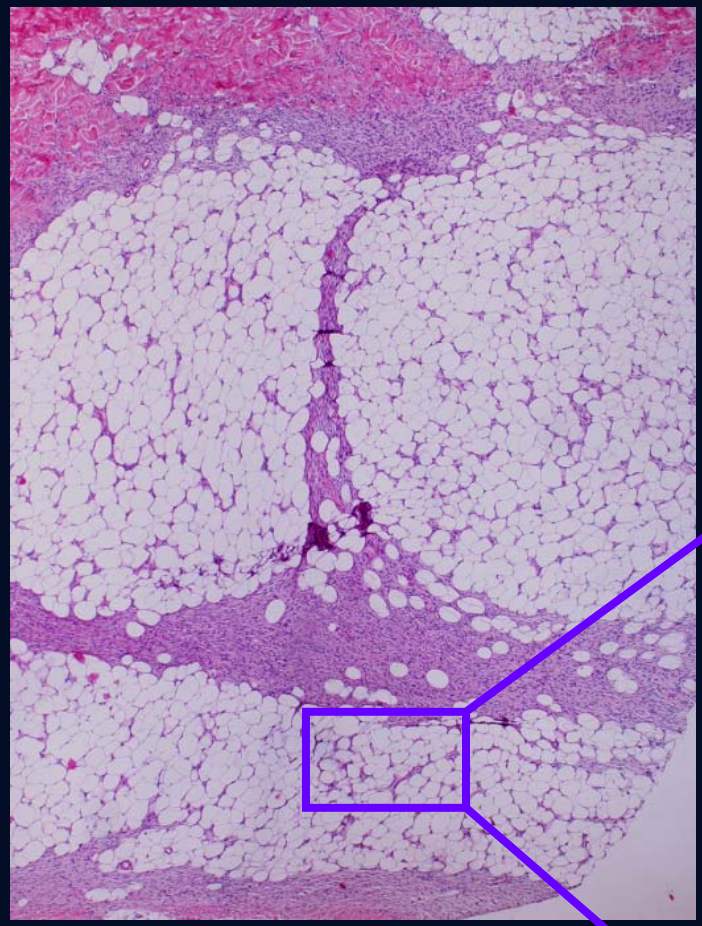

- FINGER LIKE EXTENSIONS
- SHELFLIKE TUMOUR AGGREGATES

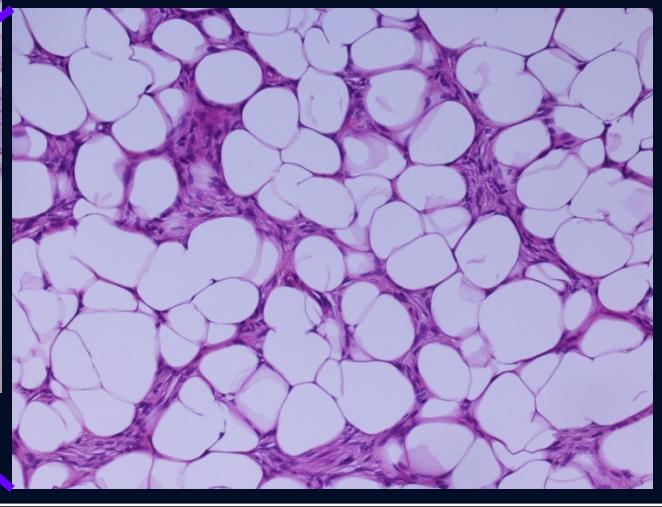

FOLLOW-UP 3 YEARS: FREE OF RECURRENT TUMOUR

V.N.

25 11'93

DERMATOFIBROSARCOMA

DFSP

LEIOMYOSARCOMA

CHONDROSARCOMA
OSTEOSARCOMA

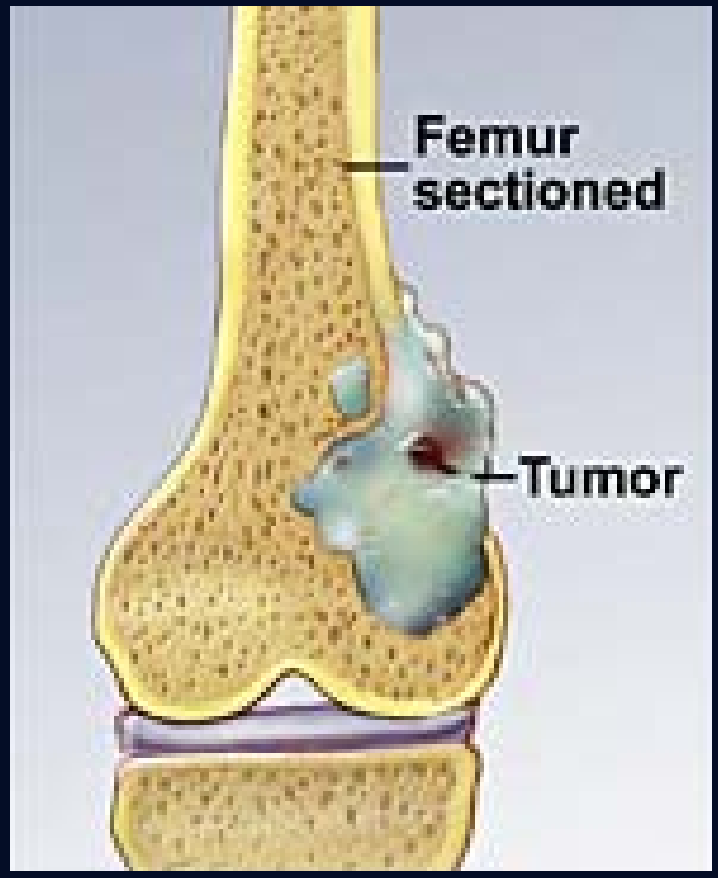

ANGIOSARCOMA

KAPOSI SARCOMA

Herpes simplex virus 8

DIFFERENTIAL DIAGNOSIS

NODULAR BCC

NODULAR BCC

PIGMENTED BASALCELLCARCINOMA

PIGMENTED BCC

HAEMANGIOMA

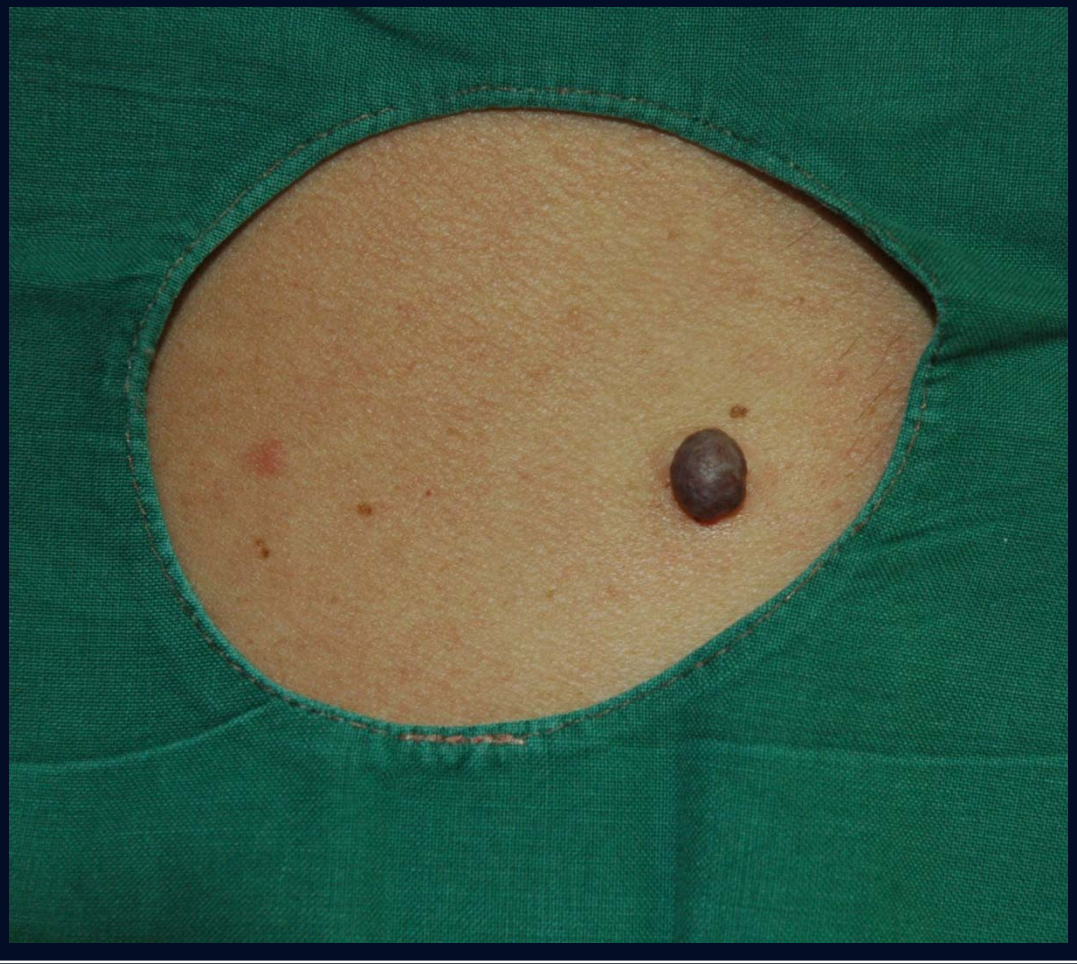

DERMATOFIBROMA

DERMATOFIBROMA

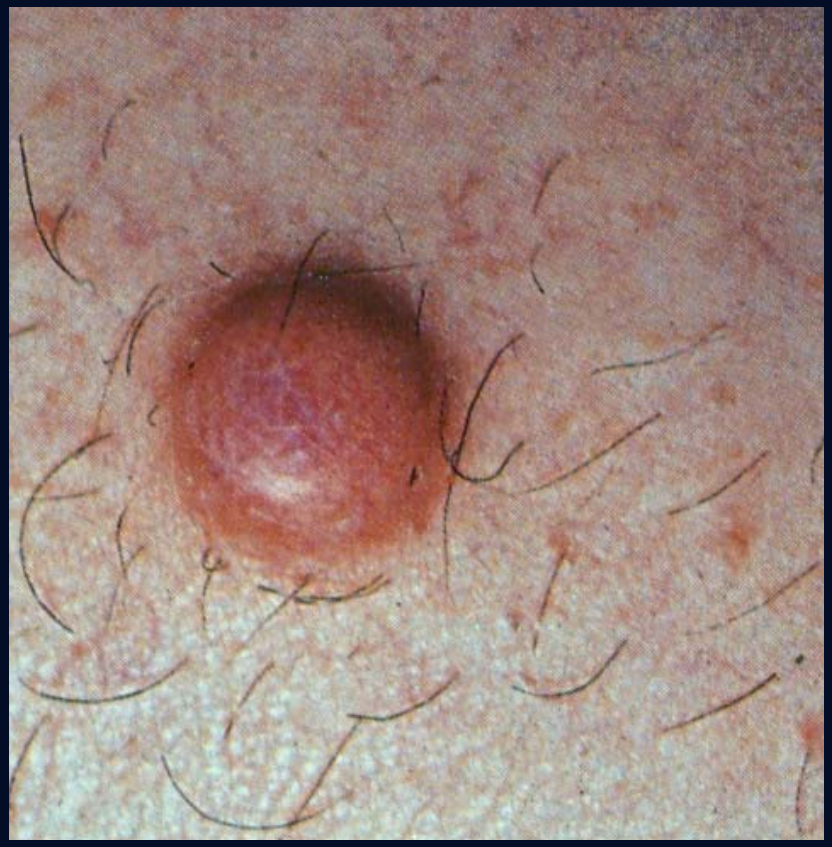

GRANULOMA PYOGENICUM

GRANULOMA PYOGENICUM

BLACK HEEL

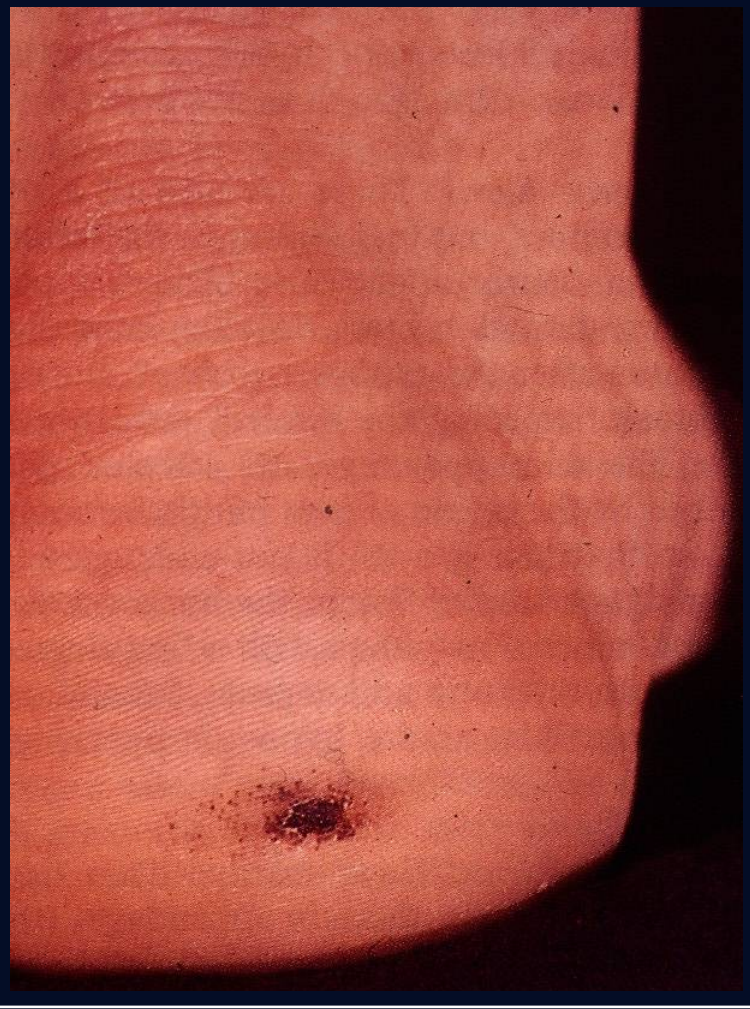

SURNUMERY NIPPLE

MELANOMA

PIGMENTED BCC

NODULAR ULCERATED BCC

AMELANOTIC MELANOMA

ANGIOKERATOMA

MELANOMA

EPIDERMAL NAEVUS

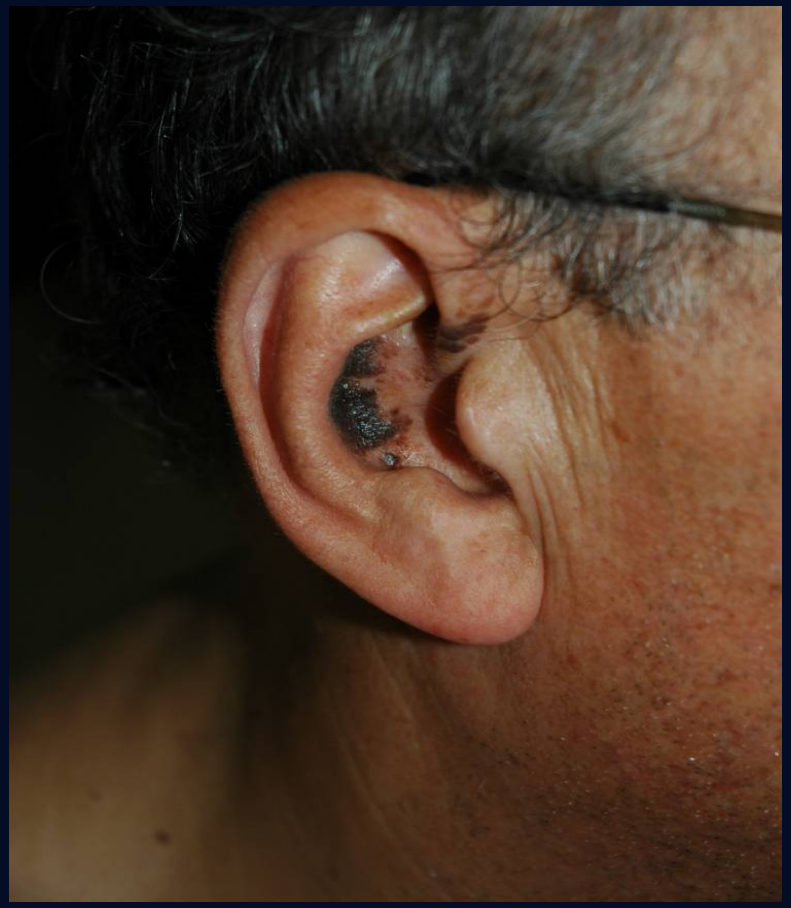

SEBORRHEIC KERATOSIS

PIGMENTED BCC

ANGIOKERATOMA

MASTOCYTOMA

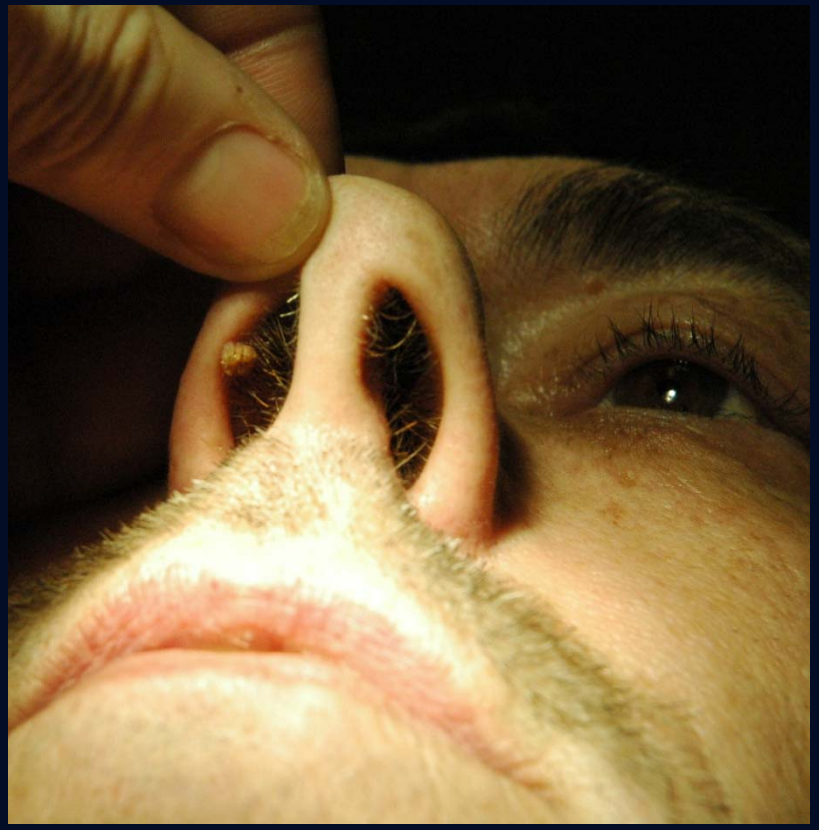

VERRUCA VULGARIS

TAKE HOME MESSAGE

- stay alert
- don’t hesitate to perform a biopsy
- education for patient and their children

THE END